








Morphology and morphometry of frontal sinuses as a tool in sex determination based on 17th–18th century skulls from Poland

Kamil Mrozek^{1,2} , *Justyna Marchewka*³ , *Beata Borowska*⁴ ,
*Alicja Budnik*³ , *Bartosz Leszczyński*⁵ , *Andrzej Wróbel*⁵ ,
*Iwona Wronka*² 

¹ Nature Education Centre, Jagiellonian University, Krakow, Poland

² Laboratory of Anthropology, Institute of Zoology and Biomedical Research, Faculty of Biology, Jagiellonian University, Krakow, Poland

³ Department of Human Biology, Institute of Biological Sciences, Cardinal Stefan Wyszyński University, Warsaw, Poland

⁴ Department of Anthropology, Faculty of Biology and Environmental Protection, University of Lodz, Poland

⁵ Department of Medical Physics, Marian Smoluchowski Institute of Physics, Jagiellonian University, Krakow, Poland

ABSTRACT: Morphological analysis of the frontal sinuses (FS) is one of the methods used to assess the sex of human remains. Depending on the methods, the results indicate the effectiveness of using the FS in the assessment of sex at the level of 60–85.9%. Our goal was to determine whether the morphological and morphometric methods of sex assessment based on the FS can be used for examining historical populations in anthropological studies. We assessed FS both morphologically and morphometrically on a sample of 76 dry skulls (41 females and 35 males) from 17th–18th century from Poland to evaluate the potential of applying this method for sex estimation in human remains. A total of 76 X-rays were taken in both frontal and lateral views. The morphology and morphometry of the FS were assessed with ImageJ software. There were no significant differences between the sexes in assessing the outline of the upper border of the FS, as well as the number of partial septa. There was a statistically significant difference between the sexes in the width of the right FS, the height of the right and left FS, and the right and left area of the FS. The lateral view indicated a statistically significant difference between the sexes regarding the depth and area of the FS. The accuracy rate in classifying males and females using FS morphometry ranged from 59.09% to 69.57%. The FS in the lateral view (69.57%) and the height of the left FS in the frontal view (68.18%) are the most appropriate regressors for sex determination. Statistically significant differences in some FS measurements between the sexes do not appear to be a sufficient indicator of sex. Morphological and morphometrical characteristics of the FS should not be used as a guideline for sex assessment in the historical Polish population.

KEY WORDS: frontal sinuses, sex dimorphism, morphology, morphometry.

Original article

© by the author, licensee Polish Anthropological Association and University of Lodz, Poland

This article is an open access article distributed under the terms and conditions of the

Creative Commons Attribution license CC-BY-NC-ND 4.0

(<https://creativecommons.org/licenses/by-nc-nd/4.0/>)

Received: 23.01.2024; Revised: 14.04.2024; Accepted: 22.04.2024



Introduction

Frontal sinuses (FS) are paired structures situated within the anterior cranial vault, posteriorly to the superciliary arches (Yoshino et al. 1987; Moideen et al. 2017). These sinuses are pneumatic cavities lined with mucosa, located between the internal and external laminae of the frontal bone. FSs are almost always asymmetric and separated by a septum. Each sinus extends superiorly to the medial end of the eyebrow ridge and back into the orbital portion of the frontal bone (Falguera et al. 2012). Their inferior margin represents the superior margin of the orbital rim and their medial margin is shared with the contralateral sinuses (Yoshino et al. 1987).

At birth, FS are small, closed pouches (Patil et al. 2012). FS pneumatization begins about two years of age, becomes significant in early adolescence, and is completed in the late teens (Hopkins 2016). The two FSs develop independently from the anterosuperior pneumatization of the frontal recess into the frontal bone and show considerable anatomical variation in size and shape. There are four basic morphological types of FS in terms of size: aplasia, hypoplasia, medium size, and hyperplasia (Guerram et al. 2014). One or both FS may be hypoplastic or absent, although bilateral aplasia is rare (McLaughlin et al. 2001). FS can also be unilateral or bilateral. The prevalent asymmetry of FS can be attributable to the fact that they develop from two independent structures (Hopkins 2016).

Research on the uniqueness of FS structures began in the early twentieth century. Schuller (1921), who examined the frontal sinuses for the first time in 1921, provided information about their unique shape, complexity, and individ-

uality, with relevance for human identification in post-mortem cases. The special characteristics of frontal sinuses in terms of their size, shape, and position made them unique personal identification tools, especially due to their irregular shape and inter-individual uniqueness (Camargo et al. 2007; Cox et al. 2009; Tang et al. 2009; Uthman et al. 2010; Xavier et al. 2015). Most studies indicate that FS can potentially be used in sex differentiation during anatomical and anthropological studies, as differences in size and configuration have been observed in males and females (Patil and Mody 2005; Uthman et al. 2010; Kim et al. 2013; Hamed et al. 2014; Sai Kiran et al. 2014; Michel et al. 2015; Thottungal et al. 2024).

However, the biological significance of the frontal sinuses is not yet clear although it has been hypothesized to have olfactory, respiratory, phonetic, static, thermal, and/or mechanical functions (Patil et al. 2012; Nikolova et al. 2017; Godinho and O'Higgins 2018). According to the prevalent theory, its presence decreases skull weight and mechanically fixes the bones of the splanchnocranium (McLaughlin et al. 2001; Teul et al. 2005; Guerram et al. 2014; Nikolova et al. 2017).

Estimation of the sex is a fundamental step in performing anthropological examinations of skeletal material (Phenice 1969; Lovell 1989; Bruce and MacLaughlin 1990; Buikstra and Ubelaker 1994; Hsiao et al. 1996; Ubelaker and Volk 2002; Spradley and Jantz 2011; Inskip et al. 2018). As the skull is one of the best-preserved body parts after death, it is considered a good material for assessing sex (Rogers 2005). The frontal bone is one of the most sexually dimorphic elements of the human

skull, due to features such as glabellar prominence, frontal eminences, and the massiveness of the supraorbital ridges (Williams and Rogers 2006). However, these features may not be applicable for sex identification when skulls are fractured and deformed. Material from archaeological sites or ossuaries is often fragmentary and thus sex assessment is often performed based on single bone fragments, which requires extracting as much information as possible from such material (Ubelaker and Wu 2020). Fragmentation of the skull prevents the use of most conventional markers for sex estimation. When bone fragmentation does not allow the use of standard methods of sex assessment, anthropologists may consider alternative methods, such as X-ray, CBCT, or histological analysis.

The present study aimed to evaluate the morphological structure of FS using posteroanterior and lateral radiographs of crania of the 17–18th century crania from Poland and to compare the findings for males and females. Metric analysis was performed and the morphological diversity was estimated in terms of FS type, the number of scallops, and septa. We estimated the height and width range for medium-sized (normal) and hyperplastic FS types for the entire sample and both sexes separately.

This study also aimed to evaluate the accuracy rate of sex identification based on frontal sinus index and area measurements and determine the dimorphic potential of the frontal sinuses. In addition, we aimed to assess the accuracy of sex estimates based on a logistic regression model, and to test a hypothesis regarding the usefulness of frontal sinus morphology as a tool for anthropologists when determining the sex of skeletal material in historical samples.

Materials and methods

The research material consisted of a series of skulls from Krakow cemeteries used by people of different socio-economic status, dating back to the 17th and 18th centuries: 1. The cemetery next to St. Mary's Basilica used by wealthy burghers (Bieniarzówna and Małecki 1984; Żukow-Karczewski 1989); 2. The cemetery next to St. Mark's Church, where a group of Krakow craftsmen of relatively low social status were buried (Zaremska 1974; Myszka 1996); 3. The cemetery next to St. Peter the Little in the hamlet of Garbary, which was located outside the city walls, on the outskirts of what was then Krakow. This cemetery used to be a burial place of the poorest Krakow residents and the inhabitants of nearby villages (Pieradzka 1931; Kracik 1989; Wyzga 2014). Figure 1 illustrates the location of all of these sites in Poland.

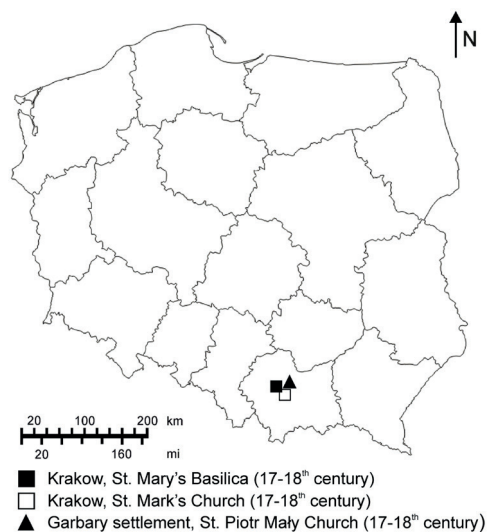


Figure 1. Map of Poland showing the geographic locations of the sites included in this research

A total of 76 skeletons that exhibited a complete epiphyseal fusion were analyzed (35 males and 41 females). The skeletons included in this study met two primary criteria. The first criterion was the completeness of the material allowing the estimation of sex and age at death, which were estimated using anthropological methods. All individuals were analyzed using the long bones, cranium, and pelvis (Phenice 1969; Lovell 1989; Bruce and MacLaughlin 1990; Buikstra and Ubelaker 1994; Ubelaker and Volk 2002; Spradley and Jantz 2011; Inskip et al. 2018). An overall sex estimate was made for each skeleton based on all the traits assessed. When general skull and pelvic estimates provided conflicting results, more weight was placed on pelvic traits which have been shown to be more reliable in sex identification compared to solely using skull features (Inskip et al. 2018). Skeletons that were ambiguous in estimating sex or those whose preservation state made it impossible to determine sex were excluded from the analysis. The estimation of age at death included evaluations of pubic symphysis (Meindl et al. 1985; Brooks and Suchey 1990), which has been shown to provide reasonable age estimates for individuals <40 years of age (Hens et al. 2008), and the eight-phase Lovejoy auricular surface method (Lovejoy et al. 1985), which provides reasonable estimates for individuals >40 years of age because the auricular surface more frequently survives taphonomic insult and its morphological changes continue well into the sixth decade of life (Hens et al. 2008). The lower limit of the age range was set at 25, as it exhibits a complete epiphyseal closure of the sternal end of the clavicle (Scheuer and Black, 2000). The second inclusion criterion was good condition of the skele-

ton, and especially a well-preserved facial part of the skull with the frontal bone.

All X-ray images were acquired by a radiologist at the Department of Descriptive Anatomy, Pomeranian Medical University to eliminate technical bias. The skulls were placed on a special platform that allowed repeatable radiographic positioning. To visualize the frontal view of the sinuses, we used the PA Axial Caldwell Method, which is a caudally angled radiograph, with its postero-anterior projection. In the Caldwell position, the FS outlines are the clearest, minimizing the risk of interpretation errors. According to Caldwell's method, the skull forehead was placed against the image detector so that the orbitomeatal line was running perpendicular to the detector. The petrous ridge was below orbits. The skulls angled caudally at 15°, the orbitomeatal line was parallel to the floor so that the central ray exited the nasion. The mid-sagittal plane was perpendicular to the midline of the image receptor. For the lateral view, we used a common routine method. The skull lay flat, raised on a thin radiolucent foam rubber pad. The infraorbitomeatal line from the inferior orbital margin to the upper border of the external auditory meatus was set perpendicularly to the table.

Only images with visible FS margins were selected for analysis. X-ray images were acquired according to the commonly accepted methodology at a focus distance of 1 m, an exposure time of 1 s, a voltage of 90–95 kV, and a current of 125 mA. The applied linear image enlargement was estimated at 1.13. In the calibration measurements, photographic film was scanned, calibrated, and saved in .jpg format. The morphological types of FS were estimated according to Gueram et al. (2014) (see Fig. 2), where aplasia indicates the absence of frontal pneu-

matization, hypoplasia indicates that FS is limited to the area under the supraorbital line, medium size indicates that FS is limited to the area medial to the mi-

dorbital line, while hyperplasia indicates that FS extends in the area lateral to the midorbital line. Some variations of FS pneumatization are shown in Figure 3.

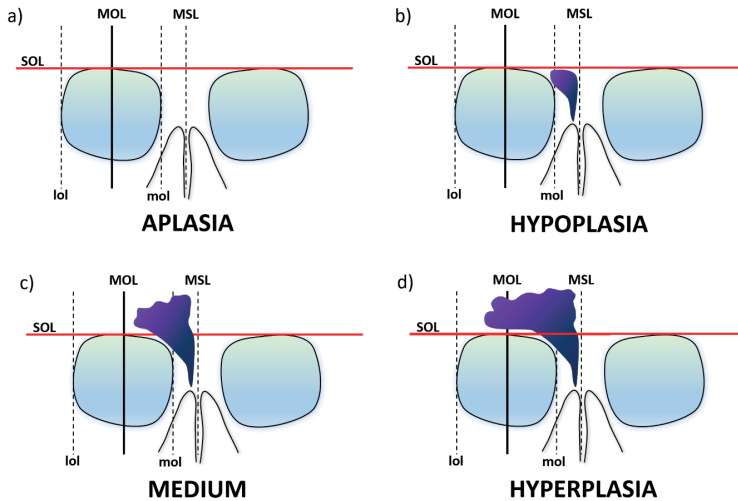


Figure 2. Morphological types of the frontal sinuses after Guerram et al. (2014): a) aplasia, b) hypoplasia, c) medium, d) hyperplasia. Where: MOL – midorbital line; SOL – supraorbital line; MSL – midsagittal line; mol – medial orbital line (vertical line passing through the most medial orbital point); lol – lateral orbital line (vertical line passing through the most lateral orbital point)

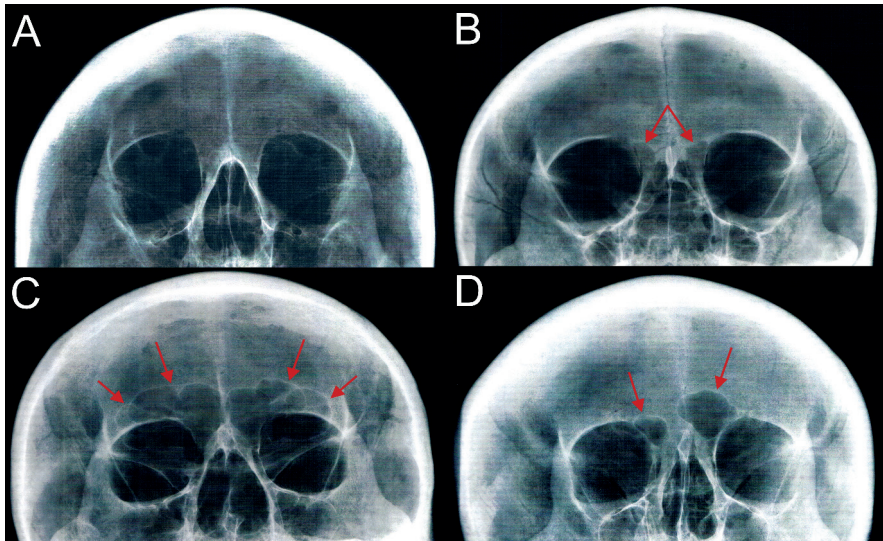


Figure 3. Variations of the frontal sinus pneumatization: A – bilateral aplasia; B – bilateral hypoplasia; C – bilateral hyperplasia; d – visible asymmetry in FS size

Based on Caldwell's diagrams (Fig. 4), the following measurements of the frontal sinuses were taken: right height, left height, right width, left width, left area, right area, and total area obtained only for the portion of the FS projected above the baseline (A). The separation between the left and right sides of the sinus was based on the frontal sinus septum to ensure that only one width was measured on each side. The highest height of each side (measurements B and C) was estimated from the maximum distance between the base and upper lines of the FS, while the largest width (measurements F and G) was estimated from the maximum distance between the medial and lateral lines of the right and left sides of the FS. The linear measurements obtained from each

radiograph were expressed in millimeters (mm), while the areas were expressed in square millimeters (mm²). Figure 5 shows a diagram of the FS measurement on lateral cephalograms. The highest (H) and lowest (L) points were observed. The maximum height (A) of the FS was obtained by connecting these points. The maximum depth (B) was measured by drawing a perpendicular line to A connecting the anterior wall of the frontal sinus in its deepest part. All measurements were obtained using the program ImageJ for Windows, and the obtained values are the arithmetic mean of three subsequent measurements. Next, the range of measurement variability was estimated separately for the normal and hyperplastic types of the FS.

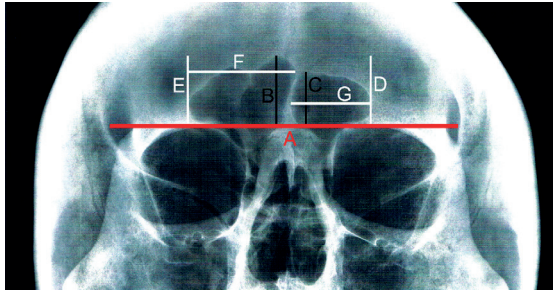


Figure 4. Diagram of Caldwell with the demarcation of the borders of the frontal sinus and identification of the measurements collected with the aid of a reference baseline: A – supraorbital line corresponding to the superior margin of the orbits; B – the height of the right FS; C – the height of the left FS; D and E – lateral lines of the FS right and left side; F – width of the right FS; G – width of the left FS

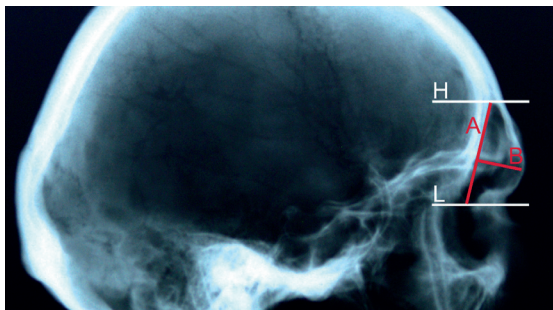


Figure 5. Frontal sinus measurements on the lateral cephalogram. H – the highest point of the FS; L – the lowest point of the FS; A – maximum height, B – maximum depth of the FS

The frontal cephalograms were divided into two main parts. The first step of the analysis involved the evaluation of the FS morphological type of FS, the variability of the upper border of FS and the classification of the number of partial septa. The second step consisted of estimating the range of variability, mean value, and standard deviation for the sinus measurements analyzed, as well as estimating the significance of sex differences. That step also included analysis of the estimated values of asymmetry indices (AI), which were calculated according to Szilvassy (1974, 1982) and Tang et al. (2009):

$$AI = \frac{\text{The value of the smaller frontal sinus measurement}}{\text{The value of a larger frontal sinus measurement}}$$

If both frontal sinuses are of the same size, the index in this case is 100 (no asymmetry). The closer the index is to 100, the smaller the asymmetry. Then, based on the features that differentiated male and female skulls, a simple logistic regression model was built.

The analysis of the lateral cephalograms included estimation of the descriptive statistics and assessment of the significance of the differences between male and female skulls. Similar to the frontal cephalograms, a logistic regression model was constructed for features that show differentiation.

Sex differences in the sinuses were also evaluated in terms of the number of scallops on the superior border (right, left and total), the number of partial septa (right, left and total), and the unilateral/bilateral presence or absence of partial septa. If the outline of the anterior margin was scalloped or lobulated, these structures were counted. A similar procedure was followed for number of partial septa. Figure 6 shows the applied method for evaluat-

ing the number of scallops and septa (after Yoshino et al. 1987), while Figure 7 shows an example of FS with scallops and septa. The outline of the upper border of the FS on each side was divided into the following categories: absent; smooth/scalloped with 1 arcade; scalloped with 2 arcades; scalloped with 3 arcades; scalloped with 4 arcades; scalloped with 5 arcades; and scalloped with 6 arcades.

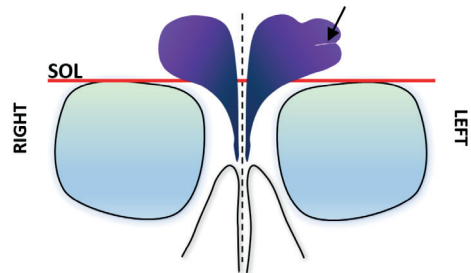


Figure 6. The upper FS border is scalloped with 3 arcades on the left and smooth on the right side. One partial septum (marked by black arrow) is present in the left sinus

To assess the inter-rater reliability study, a subset of 30 cephalometric radiographs (15 males and 15 females) were randomly chosen to be reviewed by the different observers. Observers independently drew measuring lines and made the same measurements. The intraclass correlation coefficient (ICC) was then determined in SPSS statistical package version 23 (SPSS Inc, Chicago, IL). We used ICC2 (according to McGraw and Wong's (1996) terminology) or ICC (2,k) (in Shrout and Fleiss's (1979) convention), which is a Multiple-Rating, Absolute-Agreement, 2-Way Random-Effects Model. ICC estimates indicate good reliability: ICC = 0.793 for male samples, with 95% confidence interval = 0.750–0.836, and ICC = 0.821 for female samples, with 95% confidence interval = 0.759 and 0.854.

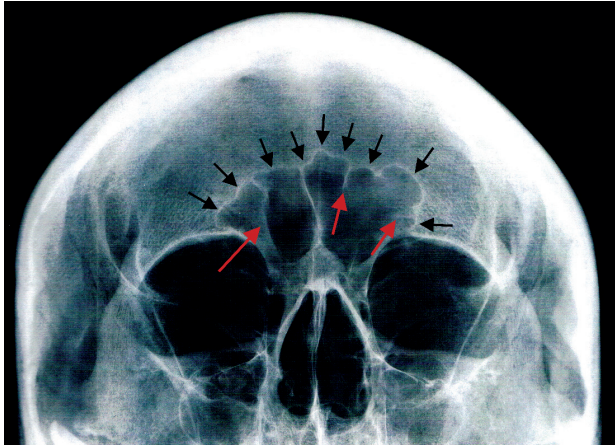


Figure 7. The upper FS border is scalloped with a few arcades (black arrows), both on the left and right sides. Red arrows indicate the septa, respectively a partial septa on the left and a complete septum on the right

Results

First, the frequency of the various FS morphological types was calculated (Tab. 1). A comparison of their estimated frequency in males and females using the Chi-squared test showed no significant differences ($p = 0.3954$ for the right side and $p = 0.3122$ for the left). In two cases, bilateral aplasia of the FS was observed. Both of those cases were male skulls with a metopic suture.

Second, the morphology of the superior border of the FS was observed and the number of scallops was noted (Tab. 2 and Tab. 3). Skulls with bilateral sinus aplasia were not included in the analysis. However, skulls with unilateral sinus aplasia were included, denoted by the column named "Absent" (Tab. 2). Data were analyzed using the Chi-squared test for comparison of the frequency of morphological type for the two sexes. No statistically significant differences between skull sides and sexes were observed ($p > 0.05$).

Table 1. Distribution of frontal sinus types in the analyzed skulls

Sex	Side	Frontal sinus type			
		Aplasia n (%)	Hypoplasia n (%)	Medium size n (%)	Hyperplasia n (%)
Female N = 41	Right	0 (0.00)	6 (14.63)	33 (80.49)	2 (4.88)
	Left	0 (0.00)	5 (12.20)	31 (75.61)	5 (12.20)
Male N = 35	Right	2 (5.71)	4 (11.43)	26 (74.29)	3 (8.57)
	Left	2 (5.71)	3 (8.57)	23 (65.71)	7 (20.00)
Total N = 76	Right	2 (2.63)	10 (13.16)	59 (77.63)	5 (6.58)
	Left	2 (2.63)	8 (10.53)	54 (71.05)	12 (15.79)

Table 2. The classification of the outline of the upper border of the frontal sinus

Sex	Side	Outline of upper border						
		Absent	Smooth / Scalloped with 1 arcade	Scalloped with 2 arcades	Scalloped with 3 arcades	Scalloped with 4 arcades	Scalloped with 5 arcades	Scalloped with 6 arcades
		n (%)	n (%)	n (%)	n (%)	n (%)	n (%)	n (%)
Female N = 38	Right	3 (7.90)	12 (31.58)	13 (34.21)	7 (18.42)	2 (5.26)	0 (0.00)	1 (2.63)
	Left	2 (5.26)	12 (31.58)	11 (28.95)	7 (18.42)	5 (13.16)	1 (2.63)	0 (0.00)
	Chi-squared test R vs L					$p = 0.6326$		
Male N = 31	Right	2 (6.46)	6 (19.35)	9 (29.04)	6 (19.35)	5 (16.13)	2 (6.45)	1 (3.22)
	Left	1 (3.22)	5 (16.13)	11 (35.49)	4 (12.91)	6 (19.35)	3 (9.68)	1 (3.22)
	Chi-squared test R vs L					$p = 0.9664$		
Total N = 69	Right	5 (7.25)	18 (26.09)	22 (31.88)	13 (18.84)	7 (10.14)	2 (2.90)	2 (2.90)
	Left	3 (4.35)	17 (24.64)	22 (31.88)	11 (15.94)	11 (15.94)	4 (5.80)	1 (1.45)
	Chi-squared test R vs L					$p = 0.7499$		
Chi-squared test – sex differences					$p = 0.1877$			

Table 3. The classification of the number of the partial septa

Sex	Side	N	Number of partial septa			
			Absent	1 partial septum	2 partial septa	3 partial septa
			n (%)	n (%)	n (%)	n (%)
Female N = 36	Right	35	28 (80.00)	4 (11.43)	3 (8.57)	0 (0.00)
	Left	36	29 (80.55)	6 (16.67)	1 (2.78)	0 (0.00)
	Total	71	57 (80.28)	10 (14.09)	4 (5.63)	0 (0.00)
Chi-squared test R vs L					$p = 0.4957$	
Male N = 31	Right	30	23 (76.67)	5 (16.67)	1 (3.33)	1 (3.33)
	Left	31	20 (64.52)	7 (22.58)	2 (6.45)	2 (6.45)
	Total	61	43 (70.49)	12 (19.67)	3 (4.92)	3 (4.92)
Chi-squared test R vs L					$p = 0.7567$	
Total N = 67	Right	65	51 (78.46)	9 (13.85)	4 (6.15)	1 (1.54)
	Left	67	49 (73.13)	13 (19.40)	3 (4.48)	2 (2.99)
	Total	132	100 (75.76)	22 (16.67)	7 (5.30)	3 (2.27)
Chi-squared test R vs L					$p = 0.8408$	
Chi-squared test – sex differences					$p = 0.2333$	

The lack of significant sex differences suggests that the morphological features of the frontal sinuses are not a good predictor of sex assessment, at least in the Polish historical population.

Table 4 summarizes the descriptive statistics for sinus measurements and p -values for Student's t -tests, which was used to compare the significance of differ-

ences between the sides and sexes. Prior to the test, the normality of distribution was established. The results indicate the absence of any statistically significant differences between the body sides in terms of height, width, and area. In turn, statistically significant differences were observed between sexes, among all measurements except for the width of the left FS.

Table 4. Range of variability and mean values of the FS frontal view for females, males, and both sexes combined

Measurements	Sex									Student's t-test – sex differences
	Female			Male			Total			
	n	Range	Mean (SD)	n	Range	Mean (SD)	n	Range	Mean (SD)	
WFS_R [mm]	35	6.64– 33.85	21.13 (7.63)	29	5.67– 41.31	26.94 (7.52)	64	5.67– 41.31	23.86 (8.03)	$p = 0.004$
WFS_L [mm]	36	5.84– 42.78	23.15 (8.45)	30	8.87– 51.18	26.57 (10.36)	66	5.84– 51.18	24.71 (9.45)	$p = 0.145$
Student's t-test – WFS R vs L	$p = 0.3385$			$p = 0.8751$			$p = 0.5849$			
HFS_R [mm]	35	0.87– 25.58	11.45 (5.81)	29	1.43– 30.15	14.87 (5.49)	64	0.87– 30.15	13.00 (5.88)	$p = 0.019$
HFS_L [mm]	36	2.12– 21.55	12.41 (4.92)	30	2.94– 35.26	16.15 (7.73)	66	2.12– 35.26	14.11 (6.57)	$p = 0.020$
Student's t-test – HFS R vs L	$p = 0.3133$			$p = 0.4688$			$p = 0.3138$			
AFS_R [mm ²]	35	0.70– 49.72	19.95 (13.76)	29	0.59– 66.84	30.28 (14.90)	64	0.59– 66.84	24.72 (15.10)	$p = 0.005$
AFS_L [mm ²]	36	0.86– 56.88	23.29 (14.01)	30	1.95– 94.10	34.76 (23.44)	66	0.86– 94.10	28.41 (19.51)	$p = 0.017$
Student's t-test – AFS R vs L	$p = 0.4559$			$p = 0.3833$			$p = 0.2298$			

WFS_R – width of the right frontal sinus; WFS_L – width of the left frontal sinus; HFS_R – height of the right frontal sinus; HFS_L – height of the left frontal sinus; AFS_R – area of the right frontal sinus; AFS_L – the area of the left frontal sinus; WFS – width of the frontal sinus; HFS – the height of the frontal sinus; AFS – the area of the left frontal sinus

The asymmetry index (AI) was calculated according to Szilvassy (1974, 1982) and Tang et al. (2009). Descriptive statistics and the evaluation of differences in the mean AI value between the sexes are summarized in Table 5. The average values of height-width indices are very similar for both sexes and indicate the lack of asymmetry in both the female sample (72.19 WFS AI and 37.01 HFS AI) and the male sample (77.33 WFS AI and 69.33 HFS AI). Slightly lower average values were obtained for the area index (60.13 AFS AI in women and 58.68 AFS AI in men). No statistically significant differences between males and females were found in mean AI values for all the measurements analyzed.

Table 6 summarizes the descriptive statistics for sinus measurements along with *p*-values for Student's *t*-tests, which was used to determine whether there were significant sex differences. Prior to the test, the normality of distribution and the ratio of FS height and depth (Frontal Sinus Index – FSI) was calculated.

The results indicated no significant sex differences in FS height and frontal sinus index (FSI). In contrast, significant differences were found for FS depth (DFS) and FS area (AFS) measurements.

In the next part of the study, a simple logistic regression model was built based on different variables presented in Table 7. In the case of osteological materials, damage to the squamous part of a frontal bone is often observed, which may result in the inability to perform all required measurements. When considering the potential fragmentation of the frontal bone in the supraorbital region, we decided to present the results for single variables, which may be more useful in the daily work of anthropologists.

The accuracy rate for classifying females and males ranged from 59.09% to 69.57%. The model shows that the frontal sinus area in the lateral view (69.57%) and the height of the left frontal sinus in the frontal view (68.18%) are the most suitable regressors for sex determination.

Table 5. Asymmetry index (AI)

AI	Sex								
	Female			Male			Total		
	n	Range	Mean (SD)	n	Range	Mean (SD)	n	Range	Mean (SD)
WFS AI	33	24.06–98.95	72.19 (18.63)	28	25.15–99.03	77.33 (18.06)	61	24.06–99.03	74.55 (18.40)
Student's <i>t</i> -test – WFS AI	<i>p</i> = 0.534								
HFS AI	33	7.84–99.24	73.01 (25.54)	28	18.03–99.31	69.33 (19.25)	61	7.84–99.31	71.32 (22.76)
Student's <i>t</i> -test – HFS AI	<i>p</i> = 0.280								
AFS AI	33	3.10–99.67	60.13 (27.81)	28	4.68–92.97	58.68 (23.44)	61	3.10–99.67	59.47 (25.70)
Student's <i>t</i> -test – AFS AI	<i>p</i> = 0.829								

WFS AI – asymmetry index of the frontal sinus width; HFS AI – asymmetry index of the frontal sinus height; AFS AI – asymmetry index of the frontal sinus area

Table 6. Range of variability and mean values of the FS lateral view for females, males, and both sexes combined

Measurements	Sex								
	Female			Male			Total		
	n	Range	Mean (SD)	n	Range	Mean (SD)	n	Range	Mean (SD)
DFS	37	3.26–12.72	7.39 (2.03)	32	3.35–16.83	9.04 (3.35)	69	3.26–16.83	8.15 (2.83)
Student's t-test WFS – sex differences	$p = 0.015$								
HFS	37	9.86–35.79	23.21 (6.45)	32	4.09–48.25	26.00 (8.65)	69	4.09–48.25	24.51 (7.62)
Student's t-test HFS – sex differences	$p = 0.131$								
AFS	37	2.33–30.65	14.65 (6.43)	32	1.92–48.28	19.61 (11.75)	69	1.92–48.28	16.95 (9.54)
Student's t-test AFS – sex differences	$p = 0.030$								
FSI	37	1.29–6.58	3.29 (1.09)	32	0.73–5.81	3.05 (1.06)	69	0.73–6.58	3.18 (1.08)
Student's t-test FSI – sex differences	$p = 0.367$								

DFS – depth of the frontal sinus; HFS – height of the frontal sinus; AFS – area of the frontal sinus; FSI – Frontal Sinus Index – the ratio of height and depth of the frontal sinus

Table 7. Simple logistic regression analysis of sex by different variables

Variables	Coefficient	SE	Wald	p value	-2 Log likelihood	χ^2 for model fit	p value	% of overall correct classification
Frontal view								
HFS_R	1.1202	0.5028	4.9052	0.0267	41.2021	5.7552	0.0164	67.19
Constant	-1.6601	0.7197	5.3202	0.0211				
HFS_L	0.9658	0.4376	4.8701	0.0273	41.6604	5.6283	0.0177	68.18
Constant	-1.5524	0.6723	5.3322	0.0209				
WFS_R	1.0242	0.3879	6.9703	0.0082	39.8270	8.5055	0.0035	65.63
Constant	-2.6713	0.9929	7.2387	0.0071				
WFS_L	0.3984	0.2750	2.0987	0.1474	44.3781	2.1930	0.1386	59.09
Constant	-1.1717	0.7301	2.5752	0.1085				
AFS_R	0.5124	0.1954	6.8715	0.0088	40.8203	8.0836	0.0045	63.08
Constant	-1.4294	0.5537	6.6638	0.0098				

Variables	Coefficient	SE	Wald	<i>p</i> value	-2 Log likelihood	χ^2 for model fit	<i>p</i> value	% of overall corrected classification
AFS_L	0.3319	0.1470	5.0991	0.0239	41.7589	5.8361	0.0157	67.69
Constant	-1.1634	0.4909	5.6176	0.0178				
Total area	0.4091	0.1386	8.7157	0.0032	41.3680	10.5980	0.0011	67.65
Constant	-2.2191	0.7300	9.2397	0.0024				
Sinus Index	-0.2117	0.2333	0.8233	0.3642	47.2218	0.8481	0.3571	59.42
Constant	0.5258	0.7750	0.4603	0.4975				
Lateral view								
HFS	0.5069	0.3391	2.2341	0.1350	46.4587	2.3742	0.1234	63.77
Constant	-1.3920	0.8721	2.5477	0.1105				
DFS	2.2836	0.9939	5.2790	0.0216	44.5877	6.1163	0.0134	65.22
Constant	-2.0051	0.8416	5.6760	0.0172				
AFS	0.5986	0.2889	4.3010	0.0381	45.2047	4.8823	0.0214	69.57
Constant	-1.1572	0.5428	4.5456	0.0330				

HFS_R – height of the right frontal sinus; HFS_L – height of the left frontal sinus; WFS_R – width of the right frontal sinus; WFS_L – width of the left frontal sinus; AFS_R – area of the right frontal sinus; AFS_L – the area of the left frontal sinus; HFS – the height of the frontal sinus; DFS – depth of the frontal sinus; AFS – the area of the left frontal sinus; SE – standard error of the mean

After applying a multivariate logistic regression model for all measurements of the frontal projection (including measurements from both sides), the mean correctness of the sex evaluation was 73.77% (χ^2 for model fit was 21.0510 at $p = 0.00703$). Regarding measurements performed in the lateral view, the mean correctness of the sex evaluation was 68.11% (χ^2 for model fit was 6.1494 at $p = 0.1046$).

Therefore, including all measurements in the frontal sinus morphometry-based sex assessment regression model generally increases its reliability by slightly more than 5.5% to less than 15%. However, the use of all possible measurements in the model does not allow us to conclude whether the reliability of the method itself increases significantly.

Contrary to expectations and despite obtaining statistically significant results, the morphometry of the frontal sinuses does not constitute a reliable sex discriminant in the skeletal series we examined.

Discussion

Numerous attempts have been made to assess the usefulness of the upper border morphology of the FS. In order to determine the dimorphic potential of the FS, many researchers have evaluated the accuracy rate of the frontal sinus index (FSI) and area measurements in sex estimation (Yoshino et al. 1987; Riepert et al. 2001; Christensem 2005; Camargo et al. 2007; Goyal et al. 2013; Sai Kiran et al. 2014; Luo et al. 2018; Almeida Prado et al. 2021; Thottungal et al. 2024).

In this study, we aimed to compare the morphology of the sinuses in males and females and to determine whether morphometric differences can be used as an additional anthropological tool in determining the skeletal sex of historical populations.

The frontal sinus may be absent or even extend beyond the frontal region. In the skeletal series analyzed, we observed two male skulls with bilateral FS aplasia. The typical configuration of FS features two sinus cavities separated by a bony septum, but variations in the number of sinus cavities have been reported.

The typical FS configuration features two sinus cavities separated by a bony septum, but variations have been reported regarding the number of sinus cavities present. The FS may be absent or even extend beyond the frontal region. The presence of three or more sinus lobes is considered to be quite rare (Phrabhakaran et al. 1999), while some studies suggest that double and triple (Schaeffer 1916; Açar et al. 2020), or even quadruple and quintuple cavities (Cryer 1907) are quite common.

In the present study, FSs were classified into four types of pneumatization. The medium-sized FS type was the most prevalent on both sides, both in males and females (77.63% and 71.05% on the right and left sides, respectively), which is consistent with the results reported by Guerram et al. (2014). In turn, Yazuci (2019) reported that hyperplasia was the most widespread type of FS in males, while aplasia and hypoplasia were predominant in females. The predominance of hyperplastic FS in males may be due to their overall relative size.

In the analyzed skeletal series, we observed two male skulls with bilateral aplasia of the FS (2.63%). Studies indicate that complete absence of FS oc-

curs in approximately 0–15% of adults (Yoshino et al. 1987; Çakur et al. 2011; Guerram et al. 2014; Belaldavar et al. 2014; Yüksel Aslier et al. 2016; Duzer et al. 2017; Pajic et al. 2017; Luo et al. 2018; Butaric et al. 2020) and the rate may vary between different geographic groups, climate, extent of supraorbital ridges, ancestry, cranial indices, or presence of a metopic suture (see, e.g., Ikeda 1980; Gulisano et al. 1987; Harris et al. 1987; Donald et al. 1994; Christensen and Hatch 2018). An interesting case of high percentages of aplasia was observed in the Alaskan Inuit population: 36% of females and 25% of males (Duzer et al. 2017) and the Canadian Inuit population: 40% of females and 43% of males (Hanson and Owsley 1980).

In the present study, the upper border of the frontal sinuses scalloped with two arcades was the most frequent type of morphology, both in females and males (31.88% total), while Yoshino et al. (1987) reported FS smooth or scalloped FS with one arcade as the most frequent in the Japanese population. In turn, in Tang et al. (2009) the most frequently recorded FS type was scalloped with two arcades on the left side (26.7%) and scalloped with three arcades on the right side (27.3%). These discrepancies are probably due to population or geographical differences.

The study by Yoshino et al. (1987) and Luo et al. (2018) and our findings suggest the absence of a partial septum as the most common morphological feature in the populations studied or skeletal series. The authors also obtained similar values for the FSI for women and men in the lateral view.

Some researchers have attempted to use morphometric diversity of the frontal sinuses and frontal sinus indices to assess sex (Goyal et al. 2013; Belaldavar

et al. 2014; Sai Kiran et al. 2014; Michel et al. 2015; Luo et al. 2018). Some studies showed a strong indication of a difference between groups of men and women for most of the variables studied (Belaldavar et al. 2014, our data). Some studies indicated that single indicators, such as width of frontal sine (Sai Kiran et al. 2014), height and depth of frontal sine (Hamed et al. 2014; Shamlou and Tallman 2022), or total FS volume/area, are the most discriminant (Michel et al. 2015). However, in most cases, the frontal sinus index revealed statistically significant sexual dimorphism ($p > 0.05$) and was thought to be a comparatively better indicator of sex determination. According to Grummons et al. (1987), ratios are more reliable compared to individual absolute measurements because of the inherent shortcomings of cephalometry, such as magnification.

According to a study by Tang et al. (2009), the height and width asymmetry index of bilateral frontal sinuses in the Chinese Han population was slightly higher (both height and width were in the range of 80–100) compared to those reported in this study (average 71.32 for height and 74.55 for width). In our study the height and width ratio was not statistically significant compared to individual measurements. This might be due to variation between skeletal series, and differences in the literature data in this respect could be linked to the variability of sexual dimorphism in different populations. However, some researchers argued that although the FSI method was superior to others, it had little potential because it consistently produced a low percentage of correct classifications, only slightly better than individual measurements (Buckland-Wright 1970; Cameriere et al. 2005; Goyal et al. 2013; Belaldavar et al. 2014).

All skulls in the present study had asymmetric FS, which is attributable to independent pneumatization processes of the right and left FS. According to the literature, 85.7% of individuals exhibit asymmetry of FS height and width: 50.1% have left-sided dominance and 35.6% have right-sided dominance while the remaining 14.3% reveal symmetric sinuses (Basic et al. 2004; Kanat et al. 2015). Larger left FSs in both sexes were also recorded by Spaeth et al. (1997) and Pondé et al. (2003) and was observed in the present study for all three types of pneumatization separately and for all types combined.

Previous studies reported variation in FS size depending on the individual's sex (Ruiz et al. 2004). Our results indicate that all absolute means measurements were higher/wider for male skulls, including the FS area (both in frontal and lateral view), but not all reached statistical significance. Buckland-Wright (1970) was one of the first authors to report sex differences, stating that the FSs in males were approximately twice as large as in females. The morphological differences in the cranium between the two sexes are considered to be mainly caused by genetic factors, more so than by nutritional, hormonal, or muscular factors (Quatrehomme et al. 1996; Patil and Mody 2005), which can explain why the FSs of men are on average larger compared to those observed in women (Szilvassy 1981).

In our study, statistically significant differences were obtained for most measurements in the frontal view (except for the width of the left side) and for the depth and the area of the frontal sine in the lateral view. Similarly significant differences between men and women in a variety of metric (e.g., total volume, width, height, depth, angle) and non-metric traits

(bilateral asymmetry, sinus shape) were obtained in several other studies (Kim et al. 2013; Hamed et al. 2014; Michel et al. 2015; Wanzeler et al. (2019).

In contrast, Yoshino et al. (1987) and Cox et al. (2009), who also evaluated anteroposterior radiographs, found no significant sexual dimorphism. Both studies indicated a sceptical view regarding the value of FS in sex assessment, suggesting too high interindividual variability of the sinuses.

Our results of the correct discrimination rate are within the range reported by other researchers, i.e., 60.0–85.9% (Camargo et al. 2007; Uthman et al. 2010; Goyal et al. 2013; Belaldavar et al. 2014; Hamed et al. 2014; Sai Kiran et al. 2014; Michel et al. 2015; Luo et al. 2018; Almeida Prado et al. 2021).

Discriminant analysis reported by Uthman et al. (2010) indicated the highest empirical values. The authors correctly predicted sex from FS in 76.9% of the cases (in conjunction with skull measurements, the overall accuracy rate was 85.9%). In the model reported by Uthman et al. (2010), the height of the left sinus was the best discriminating variable, followed by the width of the right sinus.

It should be emphasized that the lower average correct discrimination rate was obtained based on morphological characteristics such as the number of scallops on the superior border of the sinuses, the number of partial septa, and the unilateral/bilateral presence or absence of partial septa or supraorbital cells. Higher values were obtained based on metric measurements of the height, width, and area of the FS.

In summary, FS provides an average accuracy for estimating sex across different populations. This may be due to their substantial morphological variability. Some researchers have suggested

that different populations express sexual dimorphism by different patterns and to different degrees, depending on variation among proximate and ultimate mechanisms, such as sexual selection, mating patterns, variation in body size, economic patterns, and non-economic role patterns (Bastir et al. 2011). Populations may show greater or lesser sexual dimorphism, translating into average male and female morphology (Walker 2008). Thus, some groups may reveal significant differences, while in others those differences may not reach statistical significance.

A significant limitation of the present study is the small sample size that might be not enough to capture the complete range of variation, as well as the fact that the exact anatomy of the frontal sinus may not be captured on radiographs due to shot angle and distance, thus reducing the reliability of research results using cephalograms (Cameriere et al. 2005). In general, the use of FSs for anthropological purposes requires a certain degree of caution. Certain environmental factors, such as hyperpneumatization caused by sport activities, disease, trauma, post-mortem changes, and differences in techniques and radiographs such as distance, angle, and orientation of the skull, can modify the image of the frontal sinus, distorting its anatomical features and morphometric analysis (Quatrehomme et al. 1996; Cameriere et al. 2005).

Biological anthropology distinguishes between estimating sex by visually examining skeletal features (nonmetric methods) and using equations based on skeletal dimensions (metric methods). Growing concerns about the subjectivity of nonmetric sex assessments have led to the implementation of ordinal scoring systems, statistical methods, and the quantification of discrete trait mor-

phology with geometric morphometric techniques that examine shape differences (Ajanović et al. 2023). Metric sex estimation is preferred due to the objectivity associated with osteometric data, but it is only possible if equations from geographically and temporally appropriate reference samples are available and if the material is not fragmentary (Chovalopoulou et al. 2018).

Despite statistically significant differences in linear measurements and areas of the FS between the sexes, our results do not support the hypothesis of the usefulness of the frontal sinuses in assessing the sex of historical skeletal materials. The accuracy rate obtained (from 59.09% to 69.57%) is insufficient. The results of this paper suggest that frontal sinuses may have limited application as predictors of sex. The obtained values of the correctness of the assessment are not high, which allows us to conclude that, when we have mixed bones (e.g., ossuaries), the assessment is unreliable, in contrast to the promising results of work in the field of forensic medicine.

In summary, the method of sex assessment based on frontal sinus morphology, which has garnered great interest in forensic medicine and forensic anthropology, is not necessarily applicable to the study of prehistoric populations.

Conflict of interests

The authors declares that there is no conflict of interests.

Authors' contributions

KM – writing-original draft preparation, writing-reviewing and editing, investigation, data curation, methodology; JM – conceptualization, formal analysis,

methodology; BB – investigation, resources, supervision; AB – investigation, validation, supervision; BL – methodology, data curation; AW – methodology, data curation; IW – investigation, resources, supervision.

Corresponding author

Kamil Mrozek, Nature Education Centre, Jagiellonian University, ul. Gronostajowa 5, 30–387 Krakow, Poland; e mail: kamil.mrozek@uj.edu.pl

References

- Açar G, Cicekcibasi AE, Koplay M, Kelesoglu KS. 2020. The Relationship Between the Pneumatization Patterns of the Frontal Sinus, Crista Galli and Nasal Septum: A Tomography Study. *Turk Neurosurg.* 30(4): 532–541. <https://doi.org/10.5137/1019-5149.JTN.26006-19.4>
- Ajanović Z, Ajanović U, Dervišević L, Hot H, Voljevic A, Talović E, Dervišević E, Hašimbegović S, Sarač-Hadžihalilović AA. 2023. Geometric Morphometrics Approach for Sex Estimation Based on the Orbital Region of Human Skulls from Bosnian Population. *Scanning.* Article e2223138. <https://doi.org/10.1155/2023/2223138>
- Almeida Prado PS, Adams K, Fernandes LC, Kranioti E. 2021. Frontal sinus as an identity and sex indicator. *Morphologie.* <https://doi.org/10.1016/j.morpho.2020.12.005>
- Basic S, Hajnsek S, Poljakovic Z, Basic M, Culic V, Zadro I. 2004. Estimation of cortical language dominance using functional transcranial Doppler sonography in left-handers. *Clin Neurophysiol.* 115: 154–160.
- Bastir M, Godoy P, Rosas A. 2011. Common Features of Sexual Dimorphism in the Cranial Airways of Different Human Populations. *Am J Phys Anthropol.* 146: 414–422.

- Belaldavar C, Kotrashetti VS, Hallikerimath SR, Kale AD. 2014. Assessment of frontal sinus dimensions to determine sexual dimorphism among Indian adults. *J Forensic Dent Sci.* 6(1): 25–30.
- Besana JL, Rogers TL. 2010. Personal identification using the frontal sinus. *J. Forensic Sci.* 55(3): 584–589.
- Bieniarzówna J, Małecki JM. 1984. *Dzieje Krakowa. Kraków w wiekach XVI–XVIII.* Wydawnictwo Literackie: Kraków.
- Brooks S, Suchey JM. 1990. Skeletal age determination based on the os pubis: a comparison of the Acsadi-Nemeskeri and Suchey-Brooks methods. *Hum Evol.* 5(3): 227–238. <https://doi.org/10.1007/BF02437238>
- Bruce ME, MacLaughlin SM. 1990. The accuracy of sex identification in European skeletal remains using the Phenice characters. *J Forensic Sci.* 35(6): 1384–1392.
- Buckland-Wright JC. 1970. A radiographic examination of frontal sinuses in early British populations. *Man* 5(3): 512–517.
- Budnik A, Pudło A. 2017. Biodemografia nowożytnego Gdańska w świetle badań nad ossuariami. *Możliwości rekonstrukcji i problemy metodyczne*, [in:] Pudło A., Henneberg M. (red.), *Nowożytnie ossuaria z klasztoru dominikańskiego w Gdańsku. Wyniki badań interdyscyplinarnych. Fontes Commentationesque ad Res Gestas Gedani et Pomeraniae* 6: 141–171.
- Buikstra JE, Ubelaker DJ. 1994. Standards for Data Collection from Human Skeletal Remains, *Arkansas Archeological Survey Research Series No. 44*, Fayetteville.
- Butaric LN, Jones GC, Garvin HM. 2020. Revisiting global patterns of frontal sinus aplasia utilizing computed tomography. *Forensic Science International*, 315, 110458. <https://doi.org/10.1016/j.forsci-int.2020.110458>
- Çakur B, Sumbullu MA, Durna NB. 2011. Aplasia and agenesis of the frontal sinus in Turkish individuals: a retrospective study using dental volumetric tomography. *Int J Med Sci.* 8(3): 278–282.
- Camargo JR, Daruge E, Prado FB, Caria PHE, Alves MC, Silva RF, Daruge Jr E. 2007. The frontal sinus morphology in radiographs of Brazilian subjects: its forensic importance. *Braz. J. Morphol. Sci.* 24(4): 239–243.
- Cameriere R, Ferrante L, Mirtella D, Rollo FU, Cingolani M. 2005. Frontal sinuses for identification: quality of classifications, possible error and potential corrections. *J of Forensic Sci.* 50(4): 770–773.
- Cattaneo C. 2007. Forensic anthropology: developments of a classical discipline in the new millennium. *Forensic Sci Int.* 165(2–3): 185–193.
- Chovalopoulou ME, Bertsatos A, Zoi I, Manolis SK, Valakos E. 2018. Reliability testing of metric methods for sex determination in ancient skeletal remains in Greece. *Mediterranean Archaeology and Archaeometry*, 18(1): 37–47. <https://doi.org/10.5281/zenodo.1069518>
- Christensen AG. 2005. Assessing the variation in individual frontal sinus outlines. *Am. J. Of Phys. Anthropol.* 127(3): 291–296.
- Christensen AM, Hatch GM. 2018. Advances in the Use of Frontal Sinuses for Human Identification. *New Perspectives in Forensic Human Skeletal Identification*, 227–240. <https://doi.org/10.1016/b978-0-12-805429-1.00020-x>
- Cox M, Malcolm M, Fairgrieve SI. 2009. A New Digital Method for the Objective Comparison of Frontal Sinuses for Identification. *Journal of Forensic Sciences* 54(4): 761–772. <https://doi.org/10.1111/j.1556-4029.2009.01075.x>
- Cryer MH. 1907. Some variations in the frontal sinuses. *JAMA* 48: 284–289.
- Donald PJ, Gluckman JL, Rice DH. 1994. *The Sinuses.* Raven Press, New York.

- Duray SM, Morter HB, Smith FJ. 1999. Morphological variation in cervical spinous processes: potential applications in the forensic identification of race from the skeleton. *J Forensic Sci.* 44(5): 937–944.
- Duzer S, Aydemir Y, Sakallioğlu O, Akyigit A, Polat C, Centiner H. 2017. Significance of paranasal sinus aplasia. *Acta Medica Mediterranea* 33: 637–640.
- Falguera JR, Fernanda Pereira SF, Aparecido NM. 2012. Frontal sinus recognition using image foresting transform and shape context. (accessed in 2012).
- Godinho RM, O'Higgins P. 2018. The biomechanical significance of the frontal sinus in Kabwe 1 (*Homo heidelbergensis*). *J Hum Evol.* 114: 141–153. <https://doi.org/10.1016/j.jhevol.2017.10.007>
- Goyal M, Acharya AB, Sattur AP, Naikmasur VG. 2013. Are frontal sinuses useful indicators of sex? *Journal of Forensic and Legal Medicine*, 20(2): 91–94. <https://doi.org/10.1016/j.jflm.2012.04.028>
- Grummons DC, Kappeyne van de Coppello MA. 1987. A frontal asymmetry analysis. *J Clin Orthod* 21: 448–465.
- Guerram A, Le Minor J-M, Renger S, Bierry G. 2014. Brief Communication: The Size of the Human Frontal Sinuses in Adults Presenting Complete Persistence of the Metopic Suture. *American Journal Of Physical Anthropology* 154: 621–627.
- Gulisano M, Pacini P, Orlandini GF, Colosi G. 1987. Anatomico-radiological findings on the frontal sinus: statistical study of 520 human cases. *Arch. Ital. Anat. Embriol.* 83, 9–32.
- Hamed SS, El-Badrawy AM, Fattah SA. 2014. Sex identification from frontal sinus using multi-detector computed tomography. *J. Forensic Radiol. Imaging* 2: 117–20. <https://doi.org/10.1016/j.jofri.2014.03.006>
- Hanson CL, Owsley DW. 1980. Frontal sinus size in Eskimo population. *Am J Phys Anthropol* 53: 251–255.
- Harris AM, Wood RE, Nortje CJ, Thomas CJ. 1987. Sex and ethnic differences of the radiographic image of the frontal region. *J. Forensic Odontostomatol.* 5: 51–57.
- Hens SM, Rastelli E, Belcastro G. 2008. Age estimation from the human Os Coxa: a test on a documented Italian collection. *J Forensic Sci.* 53(5): 1040–1043. <https://doi.org/10.1111/j.1556-4029.2008.00818.x>
- Hopkins C. 2016. Nose, nasal cavity and paranasal sinuses. In: Standing S, editor. *Gray's Anatomy: The Anatomical Basis of Clinical Practice*. Elsevier: 565–567.
- Hsiao TH, Chang HP, Liu KM. 1996. Sex estimation by discriminant function analysis of lateral radiographic cephalometry. *J Forensic Sci.* 41(5): 792–795 (September).
- Ikeda J. 1980. Interpopulation variations of the frontal sinus measurements: comparison between the Jomon and recent Japanese population. *J Anthropol Soc Nippon Suppl.* 90: 91–104.
- Inskip S, Scheib CL, Wohns AW, Ge X, Kivisild T, Robb J. 2018. Evaluating macroscopic sex estimation methods using genetically sexed archaeological material: The medieval skeletal collection from St John's Divinity School, Cambridge. *Am J Phys Anthropol.* 168(2): 340–351. <https://doi.org/10.1002/ajpa.23753>
- Işcan MY. 2001. Global forensic anthropology in the 21st century. *Forensic Sci Int.* 117(1–2): 1–6. [https://doi.org/10.1016/s0379-0738\(00\)00433-3](https://doi.org/10.1016/s0379-0738(00)00433-3)
- Kanat A, Yazar U, Ozdemir B, Coskun ZO, Erdivanil O. 2015. Frontal sinus asymmetry: Is it an effect of cranial asymmetry? X-ray analysis of 469 normal adult human frontal sinus. *Journal of Neurosciences in Rural Practice* 6(4): 511–514.
- Kim DI, Lee UY, Park SO, Kwak DS, Han SH. 2013. Identification using frontal sinus by three-dimensional reconstruction from computed tomography. *J. Forensic Sci.* 58 (1): 5–12.

- Kracik J. 1989. Miasto zatrzymuje umarłych. Krakowskie nekropolie a kultura duchowa XVII–XVIII wieku, [in:] *Z przeszłości Krakowa*, J.M. Małecki, Warszawa–Kraków: 165–182.
- Lovejoy CO, Meindl RS, Pryzbeck TR, Mensforth RP. 1985. Chronological metamorphosis of the auricular surface of the ilium: a new method for the determination of adult skeletal age at death. *Am J Phys Anthr.* 68(1): 15–28. <https://doi.org/10.1002/ajpa.1330680103>
- Lovell NC. 1989. Test of Phenice's technique for determining sex from the os pubis. *Am J Biol Anthr.* 79(1): 117–120. <https://doi.org/10.1002/ajpa.1330790112>
- Luo H, Wang J, Zhang S, Mi C. 2018. The application of frontal sinus index and frontal sinus area in sex estimation based on lateral cephalograms among Han nationality adults in Xinjiang. *Journal of Forensic and Legal Medicine* 56: 1–4. <https://doi.org/10.1016/j.jflm.2017.12.014>
- McLaughlin RB, Rehl RM, Lanza DC. 2001. Clinically relevant frontal sinus anatomy and physiology. *Otolaryngol Clin North Am.* 34(1): 1–22.
- McGraw KO, Wong SP. 1996. Forming inferences about some intraclass correlation coefficients *Psychol Methods*, 1(1): 30–46. <https://doi.org/10.1037/1082-989X.1.1.30>
- Meindl RS, Lovejoy CO, Mensforth RP, Walker RA. 1985. A revised method of age determination using the os pubis, with a review and tests of the accuracy of other current methods of pubic symphyseal aging. *Am J Phys Anthr.* 68(1): 29–45. <https://doi.org/10.1002/ajpa.1330680104>
- Michel J, Paganelli A, Varoquaux A, Piercecchi-Marti MD, Adalian P, Leonetti G, Dessi P. 2015. Estimation of sex: interest in frontal sinus 3D reconstructions. *J. Forensic Sci.* 60(2): 269–273.
- Moideen SP, Khizer Hussain Afroze M, Moihan M, Regina M, Sheriff RM, Moideen CP. 2017. Incidence of frontal sinus aplasia in Indian population. *Int J Otorhinolaryngol Head Neck Surg.* 3: 108–111.
- Myszka M. 1996. Średniowieczne i nowożytnie pochówki odkryte w kościele św. Marka w Krakowie. [in:] *Wiadomości konserwatorskie województwa krakowskiego*, Kraków, 4: 121–148.
- Nikolova S, Toneva D, Georgiev I, Lazarov N. 2017. Digital radiomorphometric analysis of the frontal sinus and assessment of the relation between persistent metopic suture and frontal sinus development. *Am J Phys Anthropol.* 00:1–15. <https://doi.org/10.1002/ajpa.23375>
- Ozcan KM, Hizli O, Sarisoy ZA, Ulusoy H, Yildirim G. Coexistence of frontal sinus hypoplasia with maxillary sinus hypoplasia: a radiological study. *Eur Arch Otorhinolaryngol.* 275(4):931–935. <https://doi.org/10.1007/s00405-018-4892-9>
- Pajic SS, Antic S, Vukicevic AM, Djordjevic N, Jovicic G, Savic Z, Saveljic I, Janović A, Pesic Z, Djuric M, Filipovic N. 2017. Trauma of the Frontal Region Is Influenced by the Volume of Frontal Sinuses. A Finite Element Study. *Frontiers in Physiology*, 8. <https://doi.org/10.3389/fphys.2017.00493>
- Patil KR, Mody RN. 2005. Estimation of sex by discriminant function analysis and stature by regression analysis: A lateral cephalometric study. *Forensic Science International*, 147(2–3): 175–180. <https://doi.org/10.1016/j.forsciint.2004.09.071>
- Patil N, Karjodkar FR, Sontakke S, Sansare K, Salvi R. 2012. Uniqueness of radiographic patterns of the frontal sinus for personal identification. *Imaging Science in Dentistry* 42: 213–217.
- Phenice TW. 1969. A newly developed visual method of sexing the os pubis, *Am J Phys Anthr.* 30(2): 297–301. <https://doi.org/10.1002/ajpa.1330300214>
- Phrabhakaran N, Naidu MDK, Subramaniam K. 1999. Anatomical variability of the

- frontal sinuses and their application in forensic identification. *Clin Anat.* 12: 16–19.
- Pieradzka K. 1931. *Garbary. Przedmieście Krakowa (13631587)*. Biblioteka Krakowska: Kraków.
- Pondé J, Metzger M, Amaral P, Machado G, Prandini M. 2003. Anatomic variations of the frontal sinus. *Minim Invasive Neurosurg.* 46(1): 29–32. <https://doi.org/10.1055/s-2003-37956>
- Quatrehomme G, Fronty P, Sapanet M, Grevin G, Baillet P, Ollier A. 1996. Identification by frontal sinus pattern in forensic anthropology. *Forensic Sci Int.* 83: 147–153.
- Riepert T, Ulmcke D, Schweden F, Nafe B. 2001. Identification of unknown dead bodies by X-ray image comparison of the skull using the X-ray simulation program FoXSIS. *Forensic Sci Int.* 117(1–2): 89–98. [https://doi.org/10.1016/s0379-0738\(00\)00452-7](https://doi.org/10.1016/s0379-0738(00)00452-7)
- Rogers T. 2005. Determining the sex of human remains through cranial morphology. *J. Forensic Sci.* 50(3): 493–500.
- Rubira-Bullen IRF, Rubira CME, Sarmiento VA, Azevedo RA. 2010. Frontal sinus size on facial plain radiographs. *J. Morphol. Sci.* 27(2): 77–81.
- Ruiz CR, Nader Wafae N. 2004. Anatomico-radiological and morphometrical study of the frontal sinus in humans. *Braz J Morphol Sci.* 21(1): 53–56.
- Sai Kiran Ch, Ramaswamy P, Khaitan T. 2014. Frontal sinus index – A new tool for sex estimation. *J Forensic Radiol Imaging* 2(2): 77–79.
- Schaeffer JP. 1916. Further observation of the anatomy of the sinus frontalis in man. *Ann Surg.* 665–671.
- Scheuer L, Black S. 2000. *Developmental Juvenile Osteology*. Elsevier Academic Press, San Diego, CA.
- Schuller A. 1921. *Das Roentgenogramm der Stirnhöhle: Ein Hilfsmittel für die Identitätsbestimmung von Schädlen*, *Monatsschr Ohrenheilkd Laryngorhinol* 55: 1617–1620.
- Shamlou AA, Tallman SD. 2022. Frontal Sinus Morphological and Dimensional Variation as Seen on Computed Tomography Scans. *Biology (Basel)*. 11(8): 1145. <https://doi.org/10.3390/biology11081145>
- Shrout PE, Fleiss JL. 1979. Intraclass correlations: Uses in assessing rater reliability. *Psychological Bulletin*, 86(2): 420–428. <https://doi.org/10.1037/0033-2909.86.2.420>
- Spaeth J, Krügelstein U, Schlöndorff G. 1997. The paranasal sinuses in CT-imaging: development from birth to age 25. *Int J Pediatr Otorhinolaryngol*, 39: 25–40.
- Spradley MK, Jantz RL. 2011. Sex estimation in forensic anthropology: skull versus postcranial elements. *J Forensic Sci.* 56(2): 289–296. <https://doi.org/10.1111/j.1556-4029.2010.01635.x>
- Stone AC, Milner GR, Pääbo S, Stoneking M. 1996. Sex determination of ancient human skeletons using DNA. *Am J Phys Anthropol.* 99(2): 231–238. [https://doi.org/10.1002/\(SICI\)1096-8644\(199602\)99:2<231::AID-AJPA1>3.0.CO;2-1](https://doi.org/10.1002/(SICI)1096-8644(199602)99:2<231::AID-AJPA1>3.0.CO;2-1)
- Szilvassy J. 1974. Die Stirnhöhlen der Schadel aus dem awarischen Graberfeld von Zwolfaxing in Niederosterreich. *Ann Naturhist Mus Wien.* 78: 109–118.
- Szilvassy J. 1981. Zur Entwicklung der Stirnhöhlen. *Anthropol. Anz. Stuttgart*, 39 (1981), 138–149.
- Szilvassy J. 1982. Zur Variation, Entwicklung und Vererbung der Stirnhöhlen. *Ann. Naturhist. Mus. Wien*, 84A: 97–125.
- Tang JP, Hu DY, Jiang FH, Yu XJ. 2009. Assessing forensic applications of the frontal sinus in a Chinese Han population. *Forensic Sci Int.* 183:104.e1–3.
- Teul I, Czerwiński F, Zbisławski W, Wojciechowska I, Nocoń I, Kołowski P. 2005. Anthropological, Biochemical and

- Genetical Analysis of Osseous Material from Medieval Church Cemetery in Szczecin, [in:] *Wszystkich rzeczy miarą jest Człowiek*, ed. Jerzemowski J, Grzybiak M, Piontek J, Gdańsk, 649–653 (in Polish).
- Torwald CR, Hoppa RD. 2005. A test of sex estimation from measurements of chest radiographs. *J Forensic Sci.* 50(4): 785–790.
- Thottungal RR, Obertova Z, Flavel A, Franklin D. 2024. Sex estimation of frontal sinus volume from computed tomography scans in a Western Australian adult population. *Anthropol Anz.* 81(2): 161–167. <https://doi.org/10.1127/anthranz/2023/1718>
- Ubelaker DH, Volk CG. 2002. A test of the Phenice Method for the estimation of sex. *J Forensic Sci.* 47(1): 19–24.
- Ubelaker DH, Wu Y. 2020. Fragment analysis in forensic anthropology. *Forensic Sci Res.* 5(4): 260–265. <https://doi.org/10.1080/20961790.2020.1811513>
- Uthman AT, Al-Rawi NH, Al-Naaimi AS, Tawfeeq AS, Suhail EH. 2010. Evaluation of frontal sinus and skull measurements using spiral CT scanning: an aid in unknown person identification. *Forensic Sci Int.* 197: 124.1–7. <https://doi.org/10.1016/j.forsciint.2009.12.064>
- Walker PL. 2008. Sexing skulls using discriminant function analysis of visually assessed traits. *Am J Phys Anthropol.* 136: 39–50.
- Wanzeler AMV, Alves-Júnior SM, Ayres L, da Costa Prestes MC, Gomes JT, Tuji FM. 2019. Sex estimation using paranasal sinus discriminant analysis: a new approach via cone beam computerized tomography volume analysis. *Int J Legal Med.* 133(6): 1977–1984. <https://doi.org/10.1007/s00414-019-02100-6>
- Williams BA, Rogers T. 2006. Evaluating the accuracy and precision of cranial Morphological traits for sex estimation *J Forensic Sci.* 51(4): 729–735.
- Wyźga M. 2014. Funkcjonowanie wiejskich cmentarzy parafii katolickich w dobie przedzoborowej na przykładzie dekanatów Nowa Góra, Skała i Proszowice z okolic Krakowa. *Kwartalnik Historii Kultury Materialnej*, 62(3): 441–462.
- Xavier TA, Terada ASSD, da Silva RHA. 2015. Forensic application of the frontal and maxillary sinus: a literature review. *J. Forensic Radiol. Imaging.* 3: 105–110.
- Yazuci D. 2019. The effect of frontal sinus pneumatization on anatomic variants of paranasal sinuses. *Eur Arch Otorhinolaryngol.* 276(4): 1049–1056. <https://doi.org/10.1007/s00405-018-5259-y>
- Yoshino M, Miyasaka S, Sato H, Seta S. 1987. Classification system of frontal sinus patterns by radiography. Its application to identification of unknown skeletal remains. *Forensic Sci Int.* 34: 289–299.
- Yüksel Aslier NG, Karabay N, Zeybek G, Keskinoglu P, Kiray A, Sütay S, Ecevit MC. 2016. The classification of frontal sinus pneumatization patterns by CT-based volumetry. *Surgical and Radiologic Anatomy*, 38(8): 923–930. <https://doi.org/10.1007/s00276-016-1644-7>
- Zaremska H. 1974. Żywi wobec umarłych. Brackie i cechowe pogrzeby w Krakowie w XVI – I połowy XVI wieku. *Kwartalnik Historyczny* 81: 733–749.
- Żukow-Karczewski M. 1989. Cmentarze dawnego Krakowa. *Echo Krakowa* 212.