



DE GRUYTER  
OPEN

ANTHROPOLOGICAL REVIEW  
Available online at: <https://doi.org/10.1515/anre-2017-0032>



# Dental signs attributed to congenital syphilis and its treatments in the Hamann-Todd Skeletal Collection

*Stella Ioannou, Maciej Henneberg*

Biological Anthropology and Comparative Anatomy Research Unit,  
The University of Adelaide, Adelaide, South Australia

**ABSTRACT:** Syphilis in the United States during the 1800s and 1900s had a high prevalence rate causing great concern to health officials. Various measures were taken to control its spread. Mercuric treatments were used up until the introduction of penicillin. The aim of this paper is to determine whether dental abnormalities related to congenital syphilis in individuals who died of syphilis or syphilis-related causes, in the Hamman Todd Osteological Collection, occur and whether mercurial treatment was effective. Hutchinson, Moon and Fournier's works were analyzed to determine dental abnormalities associated with congenital syphilis and its treatments and used as criteria. Hillson et al. (AJPA,107:25–40) standardized method of description of dental changes was used. In the Hamman Todd Osteological Collection in Cleveland, Ohio, 102 individuals had cause of death recorded in the catalogue as syphilis or lues, and 69 had causes of death relating to syphilis which included paresis (53), aortic insufficiency (15) and pericarditis (1). Thus altogether 171 individuals were studied. Dentition was examined to determine if dental abnormalities associated with congenital syphilis and its treatments were present in individuals not recorded as having congenital syphilis. Crania were examined for any osteological changes. One individual (2266) demonstrated dental malformations possibly related to the congenital disease itself, while three demonstrated dental abnormalities associated with mercuric treatments in childhood (2118, 2263 and 3097). No remarkable bone pathologies were evident on any skull. The use of pre-penicillin treatment of congenital syphilis may have been effective to maintain health into adulthood but not always in eradicating the infection. Effects of mercury on enamel formation and bone changes, need to be considered when making a differential diagnosis of syphilis/congenital syphilis.

**KEY WORDS:** congenital syphilis, hypoplasia, mercury, molars, United States

## Introduction

Syphilis in the United States was a highly prevalent disease that caused public health concerns during the 1800s and

early 1900s, with reportable cases increasing from 145.3 (per 100 000) in 1920 to 359.7 in 1940 (United States Census Bureau 1999). Various actions were taken by some states to contain

the disease, including the introduction of public programs and legislations. Programs ranged from dark-field microscopy to free, pay, and part-pay clinics (Lancet 1937a). To control the congenital form of the disease, legislation included compulsory premarital and prenatal blood tests. Those applying for a marriage license were required to have a premarital examination for syphilis and submit a certificate from a physician stating whether they were free from the disease or whether it was communicable if present (Lancet 1938a; Prebble 1938; Lancet 1940a; DePorte 1941). The restrictions by law varied between states. The prenatal examination required a pregnant woman to be tested for syphilis either during pregnancy or at the time of delivery. The birth certificate of the infant had to show whether a blood test for syphilis was made, the date of the test, and the results (Lancet 1938a; Lancet 1940b; DePorte 1941). Again, the conditions of the laws varied between states. Other control measures were also taken to contain the disease. Federal grants increased yearly to provide treatment and education to infected individuals and the general public (Lancet 1939). The number of treatment centers for syphilis reporting to public health services through state health departments increased from 713 in 1936 to 1773 in 1939 (Lancet 1939). Various methods were also employed to inform the public of syphilis: the daily press, radio, popular magazines, journals, lectures, posters, sound films, and pamphlets (Prebble 1938).

Chemotherapies including mercury, arsenic and bismuth were used in the United States to treat syphilis, including in Cleveland, Ohio (Cole et al. 1929; Conrad and McCann 1922; Lancet 1922), while mercury, arsphenamine, and potas-

sium iodide were used to treat congenital syphilis (United States. Public Health Service. Division of Venereal Diseases 1930). In the United States, the most common method of administering mercury was by injection intramuscularly or by inunction/rubs (ointments) (Wile and Elliott 1917; Conrad and McCann 1922; United States. Public Health Service. Division of Venereal Diseases 1930; Cannon and Karelitz 1931; Lancet 1937b).

The efficacy of mercury as a form of treatment for syphilis has been debated (Weatherill 1833; Goldwater 1972; O'Shea 1990; Swiderski 2008; Zuckerman 2016) even though mercury is known to be spirilicidal, reducing the number of spirochetes in cutaneous lesions (Keogh 1913; O'Shea 1990), and inducing a Jarish-Herxheimer reaction (Holmes 1984). Some physicians found mercury to be effective in producing negative Wasserman reactions (Conrad and McCann 1922; Wakerlin 1934), and in resolving signs and symptoms of the congenital syphilis after treatment (Lancet, 1858; Lancet, 1881; Lancet, 1885; Fedtchenko, 1898; Hutchinson 1888). However, there are those who argue that there are various issues that need to be considered, and there is no sufficient evidence to support the effectiveness of mercury. Some of the issues raised include that there are no in vitro studies to support mercury's efficacy (O'Shea 1990); that prior to the discovery of *Treponema pallidum*, it was difficult to diagnose syphilis, so those who were treated with mercury were presumed to have syphilis; mercury was used to treat skin lesions of the primary and secondary stage of the disease which would often clear in a few weeks without any treatment, appearing 'cured' rather than considering the nature of disease, and mercury was known to cause severe

side effects (Goldwater 1972; Swiderski 2008). Without *in vitro* studies, it is difficult to establish whether mercury was an effective form of treatment for syphilis. Even after the introduction of other treatments such as arsenic and bismuth, mercury was still used on its own and in combination with these treatments (Wakerlin 1934; Norris et al. 1939; United States. Public Health Service. Division of Venereal Diseases 1930), producing mixed results.

Venereal syphilis manifests in three stages, primary, secondary and tertiary. While skeletal involvement is rare during the primary stage (Ehrlich and Kricun 1976), and minor during the secondary stage (periosteal lesions, osteitis) (Ortner 2003; Powell and Cook 2005), these are not diagnostic of the disease. Diagnostic skeletal lesions occur during the tertiary stage of the disease. They are considered to be the *caries sicca* sequence of calvarial changes, and nodes and expansion with superficial cavitation in long bones (Hackett 1975). However, it should be noted that not all individuals infected with syphilis will develop bony changes, with frequencies of such changes occurring between 10% and 25% (Steinbock 1976) and 2–13% (Rothschild 2005). In congenital syphilis, most cases present with some form of bone manifestations during the early and late stages of the disease, however, in approximately 50% to 75% of cases, the bony changes will be minimal or will heal, thus not appearing in skeletal remains (Steinbock 1976). Skull involvement occurs in approximately 5% to 10% (Steinbock 1976), also not making it a dependable indicator of the disease.

In congenital syphilis, lesions will vary depending on the stage of the disease (early or late). Metaphysitis, peri-

ostitis, (Rosen and Solomon 1976; Sachdev et al. 1982; Rasool and Govender 1989), osteochondritis, osteomyelitis (Jaffe 1972), and diaphysitis (Rasool and Govender 1989) have been observed during the early stages of the disease. Signs observed during the late stage include frontal bossing, short maxilla, high arch palate, saddle nose (destruction of nasal bridge and cartilage), Higouménakis' sign (sternoclavicular thickening), flaring scapulae, Hutchinson's teeth, Moon's molars, and Fournier's molars (Yang 1940; Fiumara and Lessell 1970; 1983).

Dental abnormalities observed in congenital syphilis are those produced by the disease itself, and those produced by treatments containing mercury. Those considered characteristic of the disease include Hutchinson's incisor (notched), and Moon's dome shaped molar (Hutchinson 1859; 1863; Moon 1877; Fiumara and Lessell 1970; Hillson et al. 1998). Other distinct dental signs associated with congenital syphilis in the permanent dentition include sharp grove-like hypoplastic defects around the cups of the permanent canines, and Fournier's molars which demonstrate a plane-form hypoplastic defect cutting into the base of the cusps (Hillson et al. 1998). These dental changes are the result of inflictions caused by the early stage of the disease. While Fournier's molars have been observed in some cases of congenital syphilis, they are not considered to be characteristic of the disease, as they are said to occur in other growth and development conditions (Harper et al. 2011). Dental abnormalities produced by mercury are distinct from those produced by the disease itself (Hutchinson 1878; Moon 1884; Ioannou et al. 2016). The first permanent molars are considered

the “test teeth” in reference to mercury, unlike the upper central incisors, which are the “test teeth” for the disease itself (Hutchinson 1878; Hutchinson 1888), although other teeth may also be affected by mercury. Rather than affecting the entire shape of a tooth during odontogenesis, as the disease does, mercury disturbs only the formation of enamel (amelogenesis). In severe cases, mercury can affect dentine and cause molars to appear dwarfed (Hutchinson 1878). Molars affected by mercury display deficiencies in enamel on the occlusal surface and to varying degrees, appear rugged, pitted and dirty (Hutchinson 1878). In some cases, dentine is observed with multiple discolored tubercles or spines (Hutchinson 1878). The whole occlusal surface can be affected or in patches. The incisors and canines are also affected by mercury. They display linear enamel hypoplasia that crosses all incisors and canines at the same level corresponding to crown formation times. Enamel between the linear enamel hypoplasia and the incisal edge or tip of the crown is deficient. In cases where mercury has been used to treat congenital syphilis, the crescentic notch is never replicated (Hutchinson 1878). However, dental abnormalities produced by both the disease and its treatment have been observed in the same individual and the crescentic notch is present (Hutchinson 1878).

The Hamman-Todd collection at the Cleveland Museum of Natural History in Cleveland, Ohio, was visited in 2016 to examine dentitions and skulls of all individuals with a cause of death recorded as syphilis or relating to syphilis. The purpose of this paper is to describe dental changes of individuals whose cause of death is explicitly given as syphilis or syphilis-related. Since there is evidence

in the literature that mercury was used to treat syphilis in the United States, including Cleveland, Ohio, we are interested to see whether there is any dental evidence that mercury was used and whether or not it was effective.

## Materials and Methods

The original works of Hutchinson, Moon and Fournier were analyzed to determine the dental abnormalities associated with congenital syphilis and treatments containing mercury (Hutchinson 1859;1863; 1874; 1878; 1887; 1888; Moon 1877; 1884; Fournier 1886). The criteria used to identify dental stigmata associated with congenital syphilis include Hutchinson’s clinical observations of teeth in patients with congenital syphilis, Moon and Fournier’s description of the first permanent molars, and Hillson and colleagues (1998) summary of characteristic and distinct deformities in the permanent dentition. To identify dental abnormalities associated with treatments containing mercury, Hutchinson’s descriptions and illustrations of patients with congenital syphilis treated with mercury were used for comparison.

The Hamman Todd collection in Cleveland, Ohio consists of unclaimed individuals, who died between 1912 and 1928. Out of the 3726 cadaver-derived human skeletons, a total of 171 individuals who died from syphilis or syphilis related issues were examined. Out of 171 individuals, 102 were recorded in the catalogue as having a cause of death of syphilis or lues, while 69 were recorded as having a cause of death related to syphilis. The causes of death related to syphilis included paresis (53), aortic insufficiency (15) and pericarditis (1). It is possible that these recorded deaths were

medically diagnosed as Dr. Wingate Todd (who began the collection), documented age at death, sex, stock, cause of death, pathologies, and if possible, a case history of each individual (Krogman 1939). However, this is difficult to determine due to the lack of medical documentation, and as such signs of congenital syphilis and its treatments sought for.

Dentitions of the 171 individuals were examined to determine whether certain dental abnormalities associated with congenital syphilis and its treatments were present. Although the notes of causes of death did not distinguish between acquired and congenital syphilis, it can be expected that congenitally infected individuals would be among those dying later in life of syphilis, lues or related causes. Four individuals were recorded in the catalogue as having congenital syphilis but were no longer in the collection (were repatriated, returned to families), therefore were excluded from this study.

The dentitions were studied to determine: (1) whether any individuals suffered from congenital syphilis during childhood, which had not been reflected in documentation, and (2) types of dental stigmata that may be present related to congenital syphilis or its treatments. Since it is only recently, that dental signs associated with treatments containing mercury have been applied to paleopatho-

logical cases (Ioannou et al. 2015; 2016), this was an element that wanted to be explored in this collection. The cranial skeleton of individuals displaying dental abnormalities was then examined for any bone pathologies. To identify the stages of the caries sicca sequence, Hackett's (1975) standardized method was used.

## Results

The average ages at death for the individuals in the sample of 171 who died of syphilis are as follows: black adult males (46.5yrs), black adult females (39.2yrs), black females including one 13-year-old (37.8yrs), white adult males (52.6yrs), and white adult females (53.9yrs). These results fall within the average age at death range of the entire population for their respective groups in the data collected between 1910 and 1925 by the United States Census Bureau (1999) (Table 1).

In the 171 individuals, no remarkable bone pathologies were evident on any skull in the sample.

### Dental Observations of four individuals from Hamman-Todd Collection

Four out of 171 individuals demonstrated dental malformations, 2266, 2118, 2263 and 3097.

Table 1. Newborn life expectancy between 1910-1925 in death registration states of Unites States of America and average age at death of individuals having died from syphilis or syphilis related causes in the Hamman Todd Osteological Collection

	United States Census Bureau newborn life expectancy between 1910 and 1925 in death registration states in the United States		Age at death in Hamman Todd Osteological Collection, Individuals with syphilis		
	1925	1910	Average	SD	Min-max
Black males	33.8	44.9	46.5	12.9	22-84
Black females	37.5	46.7	39.2	11.7	22-73
White males	48.6	59.3	52.6	11.4	33-80
White females	52.0	62.4	53.9	15.9	28-77

### Individual 2266

Individual 2266 is a 44-year-old African American male. Cause of death was aortic insufficiency. All teeth are present except the left second premolar and the right first permanent molar. The upper central incisors demonstrate uneven incisal edges (Fig. 1). Slight concavities are evident on the central portion of the incisal edge of the upper right central incisor, and the distal portion of the incisal edge of the left central incisor. The crown surfaces of central incisors have shallow vertical grooves in the enamel, both located on the distal portion. The upper lateral incisors are peg like in shape and display isolated pits. No hypoplasia is observed in the mandibular teeth. No bone pathologies were observed.

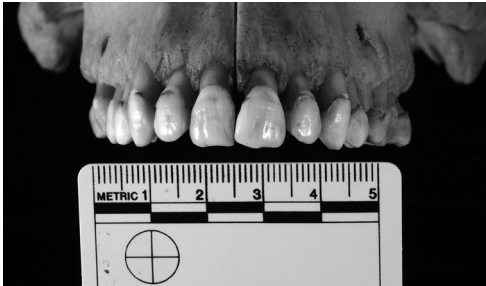

Fig. 1. Slight concavities are evident on the central portion of the incisal edge of the upper right central incisor, and the distal portion of the incisal edge of the left central incisor

### Individual 2118

2118 is a 13-year-old African American female. Cause of death was pericarditis. Skull morphology was normal. Permanent teeth include the maxillary central incisors, right lateral incisor, both canines (not fully erupted), first and second premolars (right second premolar not fully erupted), and first permanent

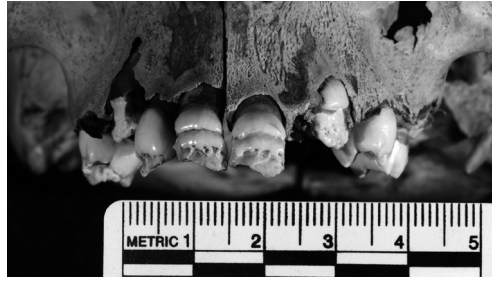

Fig. 2. Crowns of the upper central incisors, right lateral incisor, and tips of canines are severely hypoplastic, likely caused by mercury

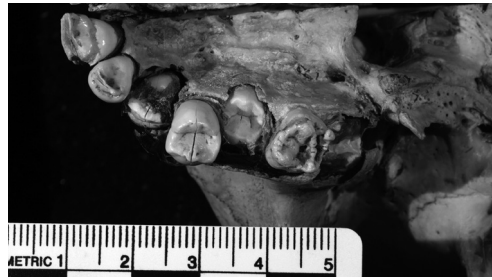

Fig. 3. Occlusal surface of the upper right permanent molar is reduced in size and hypoplastic

molars. Mandibular teeth include all incisors, both canines, right first premolar, right and left second premolars (still in crypt) and first permanent molars. The second permanent molars are still in the crypt. The crowns of the upper central incisors, up to the second third of the crown, are severely hypoplastic (pitting and linear hypoplasia) (Fig. 2). The same type of hypoplasia can be seen on the incisal third of the right lateral incisor from the middle third to the tip of the crowns of the canines. The occlusal surface of the right upper permanent molar is reduced, and hypoplastic (Fig. 3). Pitting is also observed on the occlusal surface. Severe linear and pitting hypoplasia is also observed on the mandibular anterior teeth (Fig. 4). The mandibular first permanent molars resemble the maxillary right first permanent molar (Fig. 5).

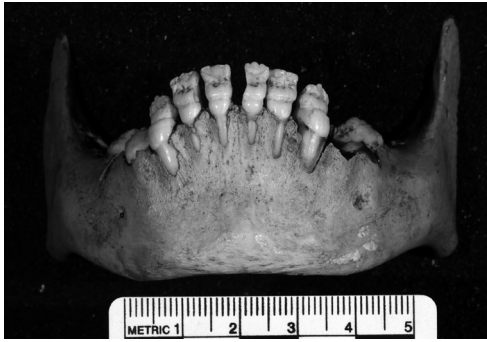

Fig. 4. All anterior teeth demonstrate pitting and linear hypoplasia. Both pitting and linear enamel hypoplasia cross all anterior teeth at the same levels

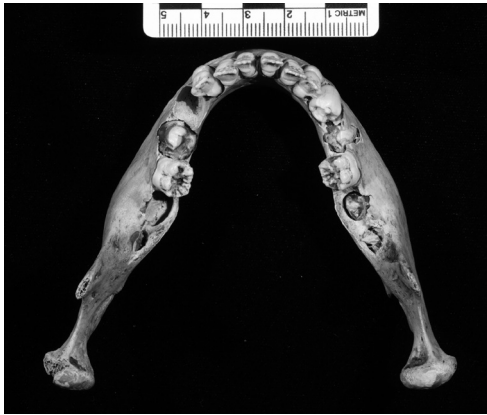

Fig. 5. The mandibular molars resemble those in the maxilla

Crowns of the upper central incisors, right lateral incisor, and tips of canines are severely hypoplastic, possibly caused by mercury. The maxilla bone in the region above the incisors shows resorptive remodeling.

### Individual 2263

Individual 2263 is a 46-years-old African American male. Lues was the cause of death. Skull morphology was normal. All maxillary and mandibular teeth are present. Linear and pitting hypoplasia is

evident on the incisal and middle third of the maxillary central right incisor and the incisal third of the lateral incisors and canines (Fig. 6). Black spots are visible on the middle third of the crown of the right central incisor. The crown of the left maxillary central incisor has broken away from the middle third of the crown to the incisal third. Black spots are just visible on the left central incisor at the same level as the right incisor. On the mandibular anterior teeth, linear and pitting enamel hypoplasia is evident on all anterior teeth at the same level (Fig. 7). The enamel of the left canine has broken off.

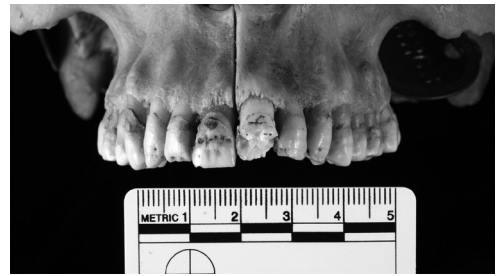

Fig. 6. The upper central incisors demonstrate linear and pitting hypoplasia on the incisal and middle third of the crowns. The same hypoplasia is evident on the incisal third of the lateral incisors and canines

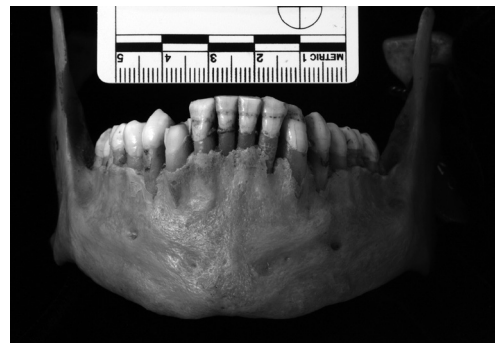


Fig. 7. Linear and pitting enamel hypoplastic defects are evident at the same level across all anterior teeth

### Individual 3097

Individual 3097 is a 36-years-old African American male. Syphilis was the cause of death. All teeth are present except for the maxillary right canine and left permanent first molar and mandibular central incisors. Minor pitting enamel hypoplasia is on the second third of maxillary central incisors. A single deep linear enamel hypoplasia runs along the cervical third of the lateral incisors and left canine (Fig. 8). This hypoplasia also occurs on the lingual surface. Along the cervical third of the central incisors are black lines that penetrate into the enamel. On the mandibular lateral incisors and canines is linear enamel hypoplasia. No bone pathologies are present.

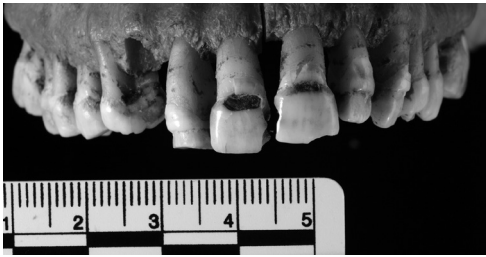


Fig. 8. Linear enamel hypoplasia runs along the cervical third of the lateral incisors and left canine. Black markings penetrate into the cervical areas of the upper central incisors, possibly carious cavities

### Differential Diagnosis

Other pathologies and chemicals can affect odontogenesis and amelogenesis and are therefore considered in making a differential diagnosis. Pathological conditions considered include tuberculosis, rickets, fluorosis, and amelogenesis imperfecta. Chemicals include mercury, arsenic, potassium iodide and bismuth.

Clinical cases of tuberculosis in children (Mignogna et al. 2000; Ito et al. 2005; Ebenezer et al. 2006), have not shown any type of enamel hypoplasia nor the dental abnormalities resembling those described in the cases above. In skeletal cases of possible tuberculosis, dental abnormalities including linear enamel hypoplasia (Matos et al. 2011; Bedić et al. 2015), bands of decreased enamel thickness and carious lesions have been observed (Formicola et al. 1987). The dental abnormalities in tuberculosis do not resemble those discussed in the above cases therefore, tuberculosis is ruled out as a possible diagnosis.

Rickets is a disorder due to a lack of vitamin D which affects bone mineralization and enamel formation. Dental abnormalities associated with this disorder include caries and enamel hypoplasia in the forms of pits and linear grooves (Zambrano et al. 2003; Davit-Béal et al. 2014). The types of enamel hypoplasia seen in rickets are not comparable to the cases from Cleveland.

Fluorosis refers to changes in enamel during tooth development, caused by ingesting large amounts of fluoride for a long period of time. In individuals with dental fluorosis enamel can appear with opaque white demarcated areas on parts or all of the tooth depending on severity, and/or be pitted or porous and may be stained yellow or brown color (Thylstrup and Fejerskov 1978; Masumo et al. 2013). The dental signs observed in fluorosis are not observed in the individuals discussed here. Fluorosis also tends to affect most or all teeth which is not seen in any cases here.

Amelogenesis imperfecta (AI) is a hereditary condition caused by a genetic mutation that interrupts the process of amelogenesis, affecting most or all



teeth in both deciduous and permanent dentition (Crawford et al. 2007; Gadhia et al. 2012). AI can cause enamel discoloration, delayed tooth eruption, tooth sensitivity, congenitally missing teeth and enamel hypoplasia (Hu et al. 2012; Wang et al. 2015). Dental abnormalities caused by AI are not evident in the cases described in this study, plus syphilis and treatments containing mercury affect specific teeth unlike AI. Therefore, AI is dismissed as a diagnosis.

Mercury was used to treat syphilis/congenital syphilis throughout Europe, the United States Asia and Australasia (United States. Public Health Service. Division of Venereal Diseases 1930). The compound used in various forms such as pills, ointments and were injected intramuscularly (Hutchinson 1887; Cole et al. 1929; Cole et al. 1933). Treatments containing mercury ranged from one and a half to fifteen grains of solution or ointment (which in milligrams equivalates to a range between 97.19 mg and 971.984 mg) (Hutchinson 1878; 1887; Lee, 1878; Warner 1881; Cole et al. 1929; Cole 1933). Established in 2004, the tolerable intake of methylmercury to protect the fetus from any adverse effects is 1.6  $\mu\text{g}$  (= 0.0016 mg) per kilogram of bodyweight per week (World Health Organization, 2007). This tolerable intake is doubled for adults (3.2  $\mu\text{g}$  or 0.0032 mg). The levels of mercury used to treat congenital syphilis in the United States during the early 20<sup>th</sup> century, surpassed what was considered to be safe. Therefore, disturbances in amelogenesis are to be expected, resulting in enamel defects. While abnormalities in enamel can be present in various forms (Seow 2013), the type of hypoplasia evident in 2118, 2263 and 3097, ranges from pitting and linear hypoplasia to missing enamel. De-

fects in the secretory stage of amelogenesis are said to result in enamel that is thin or hypoplastic with either pits or grooves (Gadhia et al. 2012; Prasad et al. 2016).

Arsenic and potassium iodide have been considered as possible causes of the dental malformations observed in the four individuals in this sample since they were used as treatments for syphilis/congenital syphilis. However, they are not known to or recorded to produce dental malformations such as those observed here. Arsenic has been noted to cause tooth abrasion and sensitivity (Sunny et al. 2013) and linear hypoplasia (Konishi et al. 1977), but not major enamel defects.

Bismuth has been noted to cause pigmentation of the enamel, loosening of the teeth in case of prolonged use and a blue line on the gums (Ling 1929; McCarthy and Dexter 1935; Dean 1943). The most constant location for pigmentation was the cervical portion of the incisors (McCarthy and Dexter 1935; Dean 1943).

## Discussion

Attitudes towards syphilis have changed over the centuries. The 19<sup>th</sup> century saw physicians primarily concerned with the clinical manifestations of syphilis, and finding what they considered effective ways of treating the disease. As various treatments were not completely successful in some cases, attitudes towards syphilis in the early 20<sup>th</sup> century in the United States changed. It was now considered a social problem and a public health concern, with a focus on controlling the spread of the disease (Breakey 1896; Post 1889). Researchers were now concerned with producing an effective test

for the disease. In 1901, Jules Jean Baptiste Vincent Bordet (1870–1961) and Octave Gengou (1875–1957) produced a complementing fixation reaction (Ligon 1998; Bialynicki-Birula 2008). As a result of this discovery, a test for syphilis, known as the Wassermann reaction test, was developed by August von Wassermann, Albert Neisser and Carl Bruck in 1906 (Lancet 1925; Sachs 1925; Bialynicki-Birula 2008). This enabled a way to detect the presence of the bacterium *Treponema pallidum* discovered in 1905 by Fritz Richard Schaudinn and Paul Erich Hoffmann (Lancet 1925).

Due to the fear of the spread of syphilis, legal action was taken making syphilis a “reportable” disease (Lancet 1911). Social concerns grew, as did stigma towards certain groups including males, African Americans, prisoners and prostitutes (Shoemaker 1887; Breakey 1886; Post 1889; Lancet 1900; Lancet 1929; Lancet 1938b; Journal of the National Medical Association 1944). Government efforts could not control the disease with individuals either avoiding testing or being non-compliant in their treatment program.

An important thing to note is that, determining accumulated levels of mercury does not prove, nor disprove the use of mercury as a form of treatment in cases of congenital syphilis, since mercury has a quick excretion rate out of the human body (Bürge 1906; Cole et al. 1929). If someone was treated with mercury for two years from the age of two, and lived to adulthood, little to no mercury would be found. However, if an individual were treated with mercury closer towards the time of death, mercury levels would be detectable, as various studies have shown (Tucker 2007; Rasmussen et al. 2008; Rasmussen et al. 2013; Zucker-

man 2016). Since the excretion of mercury is the issue, it highlights the very importance of dental changes associated with treatments containing mercury and its use when considering the differential diagnosis of congenital syphilis, especially in older individuals. The interruption to amelogenesis caused by mercury produces significantly different changes to the dentition than those caused by the disease and as such should be considered when making a differential diagnosis of congenital syphilis even if levels of mercury are not detected.

If mercury was an effective form of treatment (Warner 1881; Cole et al. 1929), mercury would prevent any changes in the bone from occurring, thus making a differential diagnosis of syphilis difficult. It is, however, certain that in the case of the four individuals discussed here, if mercury was used as a form of treatment, it was not effective in eradicating the pathogen, because these individuals died in adulthood from syphilis. All the treatment has done was reduce the severity of the disease so as to allow these individuals to reach adulthood which has been noted by Goldwater (1972). Alternately, these individuals may have been completely cured of congenital syphilis, but acquired the venereal form later in their lives.

In the 171 individuals given a cause of death of syphilis or syphilis-related ailments, four demonstrated dental signs (2266, 2118, 2263, 3097).

The dental abnormalities observed in 2266, are not typical of congenital syphilis, however, the shape of incisal edges may be simply due to tooth wear.

The most significant dental malformations are present in 2218. They appear to be a characteristic sign associated with treatments containing mercury,

which is plausible since mercury was used throughout the United States to treat syphilis in the early 20<sup>th</sup> century. It is possible that 2218 would have been administered treatment not long after birth and the treatment ceased at approximately 2.0–2.5 years of age. Crown calcification of the maxillary central incisors begins approximately 3–4 months after birth and crown completion occurs approximately at four to five years. Due to the extensive damage to the enamel on the first and second thirds of the crown of the central maxillary incisors, it is plausible that a large dose of mercury would have been administered. The permanent molars resemble those observed in syphilitic patients in the United Kingdom by Hutchinson (1878), from Australia (B70) (Ioannou et al. 2015) and Austria (Gaul and Grossschmidt 2014). Despite the large doses of mercury, the individual was not completely cured and died of syphilis later.

The enamel malformations in 2263, suggest that he may have been treated with mercury, however, the severity is not of the same extent as those observed in 2118. In this case, mercury would have been administered around 4 to 5 months after birth and treatment ceased around 3.5 years of age. It is difficult to determine whether treatment was regular or intermittent. The fact that treatment would have lasted for some years is not unusual as treatment could last up to two years (Hutchinson 1888; O’Leary et al. 1937). The concentration of mercury may have also varied, which was also common (Wernigk 1908). Despite the administration of mercury, the individual was not completely cured and died of syphilis later.

It is possible that 3097 could have been treated with mercury, which could

have lasted a couple of years as lateral incisors, and canines are affected. The cervical portions of central incisors are discolored possibly due to mercury. The discoloration could also be a carious defect caused by thinned enamel, which may have been the result of mercuric treatment. Alveolar resorption may have been caused by mercuric treatment administered during adulthood, due to reinfection, or disease resurgence.

Mercury was widely used to treat and contain the disease. As our analysis of age at death shows, individuals who were given mercury were surviving to the average age of other members of the population with no morphological changes to the skull in cases of congenital syphilis. The earliest age at death among studied skeletal remains is 13 years, which indicates that this person survived congenital syphilis for at least 10 years after possible treatment.

The fact that the vast majority of individuals recorded as dying of syphilis show no bone changes makes it difficult to confirm recorded diagnosis of syphilis by a paleopathological observation. In studies of skeletal remains from the New or Old World, absence of syphilis-related bone pathologies does not confirm the absence of the disease. Antibiotics were not available during the early 20<sup>th</sup> century, resulting in the use of metallic antibacterials. Throughout the United States, including Cleveland, Ohio, mercury was used to treat syphilis and congenital syphilis (Cole et al. 1929; Driver and Barney 1935). The paucity of bone pathologies in the collection studied and the high age at death of affected individuals, indicate that metallic antibacterial treatments were largely effective, if not in complete elimination of bacterial infection, at least in limiting seriously its

pathological effects. Comparison of very infrequent changes found in the Hamman Todd Collection with findings of Steinbock (1976) and Rothschild (2005) of frequencies reaching up to 25% or 13% of bony changes in syphilitic individuals confirms the observation of successful pre-antibiotic treatments. In cases studied here, either mercury was effective or syphilis was asymptomatic more often than in individuals studied by others. Depending on the exact components used and the timing of treatment, mercury may not have been as toxic as currently thought since individuals with congenital syphilis treated at a young age, as indicated by dental changes, lived to adulthood. A majority of other syphilitic adult individuals in this sample either had no teeth, had loose teeth or dentures. It could be possible that some individuals may have been treated with mercury at some stage during adulthood, which increases the likelihood of tooth loss. However, tooth loss could be the result of other causes.

A major limitation of this study is the fact that only individuals with cause of death recorded as syphilis or syphilis-related were studied. Were the pre-antibiotic treatments of syphilis really effective, the individuals who died of conditions not related to syphilis, but showed signs of congenital syphilis or its mercuric treatment, would be the best proof of the treatment's effectiveness.

### Conclusion

Determining syphilis in skeletal samples can be difficult due to a number of issues. The effects of treatments containing mercury, on enamel formation and bone changes, need to be considered and applied when making a differential diagno-

sis of syphilis/congenital syphilis as this may be a good indication of the disease without the presence of bone changes. The most reliable way to know whether someone with congenital syphilis was treated with mercury is by changes in enamel formation. If the individuals in this sample were treated with mercury, whether in childhood or as adults, mercury may have been effective in limiting or eradicating the infection due to the lack of notable bone pathologies.

### Acknowledgements

The authors would like to thank Mr. Lyman Jellman from the Department of Physical Anthropology at the Cleveland Natural History Museum for the invitation to examine the Hamman Todd Osteological Collection. The first author would like to acknowledge the Australian Government Research Training Program Scholarship.

### Authors' contributions

SI visited and examined the Hamman Todd Osteological Collection in Cleveland, Ohio, came up with the concept of the manuscript, wrote the manuscript, and took the photographs for the manuscript. MH examined photographs, calculated standard deviations for table, provided feedback, and edited the manuscript.

### Conflict of interest

Authors declare that there is no conflict of interests.

### Corresponding Author

Stella Ioannou, Adelaide Medical School,  
The University of Adelaide, Adelaide  
5005, South Australia, Australia  
e-mail: stelzy\_25@hotmail.com

### References

- Bedić Ž, Vyroubal V, Tkalčec T, Šlaus M. 2015. A case of childhood tuberculosis from modern period burial from Crkvari, Northern Croatia. *Podravina: J Multi Discip Res* 14(28):64–72.
- Bialynicki-Birula R. 2008. The 100th anniversary of Wassermann-Neisser-Bruck reaction. *Clin Dermatol* 26(1):79–88.
- Breakey WF. 1896. Syphilis and marriage. *JAMA* XXVII(24):1231–33.
- Bürgi E. 1906. Größe und Verlauf der Quecksilberausscheidung durch die Nieren bei den verschiedenen üblichen Kuren. *Arch Dermatol Syph* 79(1):3–30.
- Cannon AB, Karelitz MB. 1931. The comparative value of the arsphenamines in the treatment of early syphilis. *JAMA* 97:1523–30.
- Cole HN, Gammel J, Schreiber NE, Sollmann T. 1929. Mercuric salicylate: A study of its excretion in the treatment of syphilis. *Arch Derm Syphilol* 19(1):105–18.
- Cole HN, De Wolf HF, Schreiber NE, Sollmann T, Van Cleve J. 1933. Mercurial inunctions in the treatment of syphilis: Excretion of mercury following the use of mild mercurous chloride inunctions; mode of absorption of mercury from skin. *Arch Derm Syphilol* 27(1):1–11.
- Conrad AH, McCann CH. 1922. XXVI. Results in the treatment of Wassermann-fast syphilis by intravenous mercuric chloride. *Arch Derm Syphilol* 6(1):50–4.
- Crawford PJM, Aldred M, Bloch-Zupan A. 2007. Amelogenesis imperfecta. *Orphanet J Rare Dis* 2:1–11.
- Davit – Beal T, Gabay J, Antonioli P, Masle – Farquhar J, Wolikow M. 2014. Dental complications of rickets in early childhood: case report on 2 young girls. (Case study). *Pediatr* 133(4): e1077–e81.
- Dean MR. 1943. Oral Manifestations of Bismuth Therapy in the Treatment of Syphilis. *J Am Dent Assoc* 30(9):651 – 57.
- Deporte JV. 1941. Premarital and prenatal tests or syphilis. *Lancet* 238(6150):59.
- Driver JR, Barney RE. 1935. Cleveland dermatological society and American Medical Association, secretion on dermatology and syphilology. *Arch Derm Syphilol* 31(5):718–26.
- Ebenezer J, Samuel R, Matthew G, Koshy S, Chacko R, Jesudason M. 2006. Primary oral tuberculosis: Report of two cases. *Indian J Dent Res* 17(1):41–44.
- Ehrlich I, Kricun M. 1976. Radiographic findings in early acquired syphilis: case report and critical review. *Am J Roentgenol* 127:789–92.
- Fedtschenko. 1898. Treatment of Infantile Syphilis by Hypodermatic Injections of Mercury. *Am J Med Sci.* 116:604–605.
- Fiumara NJ, Lessell S. 1970. Manifestations of late congenital syphilis: an analysis of 271 patients. *Arch. Dermatol* 102(1):78–83.
- Fiumara NJ, Lessell S. 1983. The stigmata of late congenital syphilis: an analysis of 100 patients. *Sex Transm Dis* 10(3):126–29.
- Formicola V, Milanese Q, Scarsini C. 1987. Evidence of spinal tuberculosis at the beginning of the fourth millennium BC from Arene Candide cave (Liguria, Italy). *Am J Phys Anthropol* 72(1):1–6.
- Fournier A. 1886. *La syphilis héréditaire tardive*. Paris: G. Masson.
- Gadhia K, McDonald S, Arkutu N, Malik K. 2012. Amelogenesis imperfecta: an introduction. *Br Dent J* 212:377–379.
- Gaul JS, Grossschmidt K. 2014. A probable case of congenital syphilis from 18th century Vienna. *Int J Paleopathol* 6:34–43.
- Goldwater LJ. 1972. *Mercury: A history to quicksilver*. Baltimore: York Press.
- Hackett CJ. 1975. An introduction to diagnostic criteria of syphilis, treponarid and yaws (treponematoses) in dry bones,

- and some implications. *Virchows Arch A Pathol Anat Histo* 368(3):229–41.
- Harper KN, Zuckerman MK, Harper ML, Kingston JD, Armelagos GJ. 2011. The origin and antiquity of syphilis revisited: An appraisal of Old World pre-Columbian evidence for treponemal infection. *Am J Phys Anthropol* 146(S53):99–133.
- Hillson S, Grigson C, Bond S. 1998. Dental defects of congenital syphilis. *Am J Phys Anthropol* 107(1):25–40.
- Holmes K. 1984. Syphilis. In: K Holmes, editor. *Sexually transmitted diseases*. New York: McGraw Hill. 288–380.
- Hu JC-C, Chan H-C, Simmer SG, Seymen F, Richardson AS, Hu et al. 2012. Amelogenesis Imperfecta in Two Families with Defined AMELX Deletions in ARHGAP6. *PLoS ONE* 7(12):e52052.
- Hutchinson J. 1859. Transaction of the Pathological Society of London. Including the report of the proceedings for the session 1858–9. London: J.W Roche.
- Hutchinson J. 1863. A clinical memoir on certain diseases of the eye and ear, consequent of inherited syphilis: with an appended chapter of commentaries on the transmission of syphilis from parent to offspring, and its more remote consequences. London: John Churchill.
- Hutchinson, J. 1874. When and how to use mercury in syphilis. *Lancet* 103(2631):157–59.
- Hutchinson J. 1878. Illustrations of clinical surgery consisting of plates, photographs, woodcuts, diagrams etc. Illustrating surgical diseases, symptoms and accidents, also operative and other methods of treatment, with descriptive letterpress. London: J. & A. Churchill.
- Hutchinson J. 1887. Syphilis. London: Cassell & Company, Limited.
- Hutchinson J. 1888. Illustrations of clinical surgery consisting of plates, photographs, woodcuts, diagrams etc: illustration surgical diseases, symptoms and accidents, also operative and other methods of treatment, with descriptive letterpress. London: J. & A. Churchill.
- Ioannou S, Henneberg M, Henneberg RJ, Anson T. 2015. Diagnosis of Mercurial Teeth in a Possible Case of Congenital Syphilis and Tuberculosis in a 19th Century Child Skeleton. *Journal of Anthropology* 2015:1–11.
- Ioannou S, Sassani S, Henneberg M, Henneberg RJ. 2016. Diagnosing congenital syphilis using Hutchinson's method: Differentiating between syphilitic, mercurial, and syphilitic-mercurial dental defects. *Am J Phys Anthropol* 159(4):617–29.
- Ito FA, De Andrade CR, Vargas PA, Jorge J, Lopes MA. 2005. Primary tuberculosis of the oral cavity. *Oral Dis* 11(1):50–53.
- Jaffe H. 1972. Metabolic, degenerative, and inflammatory diseases of bones and joints. Philadelphia: Lea and Febiger.
- Journal of the National Medical Association. 1944. Is the Negro More Susceptible to Syphilis than the White Man. *J Natl Med Assoc* 36:28–29.
- Keogh A. 1913. A manual of venereal diseases. London. Oxford University Press.
- Konishi K, Hara K, Kambara M, Waki T, Nihida H, Kuzushita Y et al. 1977. Epidemiological Studies of Dental Diseases in the Arsenic Poisoning of Osaka Children Caused by Morinaga Dry Milk. *J Den Heal* 27(2):69–77.
- Krogman WM. 1939. Contributions of T. Wingate Todd to anatomy and physical anthropology. *Am J Phys Anthropol* 25(2):145–86.
- Lancet*. 1858. University College Hospital. Congenital syphilis in an infant a few weeks old. *Lancet*. 72:172.
- Lancet*. 1885. Charing: Cross hospital. *Lancet*. 125(3214):613–14.
- Lancet*. 1900. The legal control of prostitution in the United States. *Lancet* 155 (3988):328.
- Lancet*. 1911. United States of America. *Lancet* 177(4571):972–73.
- Lancet*. 1922. Mercury inhalations in syphilis. *Lancet* 199(5139):387.
- Lancet*. 1925. August Von Wassermann. *Lancet* 205(5299):619.

- Lancet. 1929. United States of America. Lancet 214(5534):635–36.
- Lancet. 1937a. Venereal disease in the U.S.A: (from an occasional correspondent). Lancet 229(5921):466–67.
- Lancet. 1937b. Treatment of syphilis. Lancet 230(5952):759–60.
- Lancet. 1938a. United States of America. Lancet 231(5979):804.
- Lancet. 1938b. 1938. The diagnosis of syphilis. Lancet 232(6001):578.
- Lancet. 1939. United States of America. Lancet 233(6039):1226–27.
- Lancet. 1940a. United States of America. Lancet 236(6115):592.
- Lancet. 1940b. United States of America. Lancet 236(6114):572–73.
- Lee H. 1878. Note on the use of the calomel vapour bath. Lancet 111(2841):193.
- Ligon BL. 1995. Jules Bordet: Pioneer researcher in immunology and pertussis (1870–1961). *Semin Pediatr Infect Dis* 9(2):163–67.
- Ling TM. 1929. The use of bismuth in the treatment of congenital syphilis. Lancet 214(5542):1034–1035.
- Masumo R, Bårdsen A, Åstrøm AN. 2013. Developmental defects of enamel in primary teeth and association with early life course events: a study of 6–36 month old children in Manyara, Tanzania. *BMC Oral Health* 13:1–11.
- Matos V, Marques C, Lopes C. 2011. Severe vertebral collapse in a juvenile from the graveyard (13th/14th–19th centuries) of the São Miguel church (Castelo Branco, Portugal): differential palaeopathological diagnosis. *Int J Osteoarchaeol* 21:208–217.
- McCarthy FP, Dexter Jr SO. 1935. Oral Manifestations of Bismuth. *N Engl J Med* 213(8):345–353.
- Mignogna MD, Muzio LLO., Favia G, Ruoppo E, Sammartino G, Zarrelli C et al. 2000. Oral tuberculosis: a clinical evaluation of 42 cases. *Oral Dis* 6(1): 25–30.
- Moon H. 1877. On irregular and defective tooth development. In: *Transactions of the Odontological Society of Great Britain* vol. IX-New Series. London: Wyman & Sons.
- Moon H. 1884. Dental surgery. In: T Bryant, editor. *A manual for the practice of surgery*. London: J & A Churchill.
- Norris CB, Cummer CL, Driver JR. 1939. Cleveland Dermatology Society. *Arch Derm Syphilol* 39(1):162–75.
- O’Leary PA, Cole HN, Moore JE, Stokes JH, Wile UJ, Parran T et al. 1937. Cooperative clinical studies in the treatment of syphilis: asymptomatic neurosyphilis. *Arch Derm Syphilol* 35(3):387–401.
- Ortner DJ. 2003. *Identification of Pathological Conditions in Human Skeletal Remains*. Academic Press, San Diego, California.
- O’Shea JG. 1990. Two minutes with venus, two years with mercury – mercury as an antisyphilitic chemotherapeutic agent. *J R Soc Med* 83:392–95.
- Post A. 1889. Some Considerations Concerning Syphilis and Marriage. *Bost Med Surg J* 121(25):600–2.
- Powell M, Cook D. 2005. Treponematoses: inquiries into the nature of a protean disease. In: M Powell, D Cook, editors. *The myth of syphilis: the natural history of treponematoses in North America*. Gainesville, FL: University Press of Florida/ Florida Museum of Natural History. 9–63.
- Prasad MK, Laouina S, El Alloussi M, Dollfus H, Bloch-Zupan A. 2016. Amelogenesis Imperfecta: 1 Family, 2 Phenotypes, and 2 Mutated Genes. *J Dent Res* 95(13): 1457–63.
- Prebble EE. 1938. Observations on venereal disease in the United States of America. *Lancet* 232(6009):1037–40.
- Rasmussen KL, Boldsen JL, Kristensen HK, Skytte L, Hansen KL, Møhlholm L et al. 2008. Mercury levels in Danish medieval human bones. *J Archaeol Sci* 35(8):2295–2306.
- Rasmussen KL, Skytte L, Pilekær C, Lauritsen A, Boldsen JL, Leth PM et al. 2013. The distribution of mercury and other trace elements in the bones of two human individuals from medieval Denmark – the

- chemical life history hypothesis. *Herit Sci* 1(1):1–13.
- Rosen E, Solomon A. 1976. Bone lesions in early congenital syphilis. *S Afr Med J* 50(5):135–8.
- Rasool MN, Govender S. 1989. The skeletal manifestations of congenital syphilis. A review of 197 cases. *J Bone Joint Surg Br* 71:752–5.
- Rothschild BM. 2005. History of Syphilis. *Clin Infect Dis* 40(10):1454–63.
- Sachdev M, Bery K, Chawla S. 1982. Osseous manifestations in congenital syphilis: A study of 55 cases. *Clin Radiol* 33(3):319–23.
- Sachs H. 1925. August von Wassermann. *Wien Klin Wochenschr* 4(18): 902–3.
- Seow WK. 2014. Developmental defects of enamel and dentine: challenges for basic science research and clinical management. *Aust Dent J* 59(S1):143–54.
- Shoemaker JV. 1887. Syphilis, marriage and divorce: Read before the Section of Practice of Medicine, Materia Medica and Physiology, at the Thirty-Eighth Annual Meeting of the American Medical Association. *JAMA* IX(3):79–80.
- Steinbock RT. 1976. Paleopathological diagnosis and interpretation: Bone diseases in Ancient human populations. Charles C Thomas, Springfield, Illinois.
- Sunny SD, Israt B, Saha AK, Dithi AB, Illius F. 2013. Oral health of the arsenic exposed and non-exposed children in Bangladesh. *City Dent Coll J* 10(1):5–8.
- Swiderski R. 2008. Quicksilver: A history of the use, lore and effects of mercury. Jefferson, NC: MacFarland and Company, Inc.
- Thylstrup A, Fejerskov O. 1978. Clinical appearance of dental fluorosis in permanent teeth in relation to histologic changes. *Community Dent Oral Epidemiol* 6(6): 315–28.
- Tucker F. 2007. Kill or cure? The osteological evidence of the mercury treatment of syphilis in 17th to 19th century London. *Lond Archaeol* 11(8):220–4.
- United States Census Bureau Department. 1999. Section 31 20<sup>th</sup> Century Statistics. [pdf] United States Census Bureau Department. Available at: <https://www.census.gov/prod/99pubs/99statab/sec31.pdf>. [Accessed March 17 2017].
- United States. Public Health Service. Division of Venereal Diseases. (1930). Congenital syphilis: abstracts secured in the compilation of “Venereal disease information” and on file in the Division of venereal diseases; Compilation No.2, (Rev. June, 1930); issued by the United States Public Health Service for the use in its cooperative work with the state health departments / Taliaferro Clark, assistant surgeon general, chief, Division of venereal diseases. Washington, DC: United States Government Printing Office.
- Wakerlin GE. 1934. Colloidal mercury sulphide in the treatment of syphilis. *Arch Derm Syphilol* 30(1):49–58.
- Wang X, Zhao Y, Yang Y, Qin M. 2015. Novel ENAM and LAMB3 Mutations in Chinese Families with Hypoplastic Amelogenesis Imperfecta. *PLoS ONE* 10(3):e0116514.
- Warner F. 1881. East London hospital for children: cases of congenital syphilis. *Lancet* 117 (2996): 173–4.
- Weatherill T. 1833. Extraordinary ravages of syphilis and mercury on the human countenance. *Lancet* 20(511):357–9.
- Wernigk R. 1908. Twelve years’ experience in treatment of syphilis by intravenous injections of mercury, arsenic and iodid of sodium. *JAMA* L(8):609.
- Wile UJ, Elliott JA. 1917. Mode of absorption of mercury in the inunction treatment of syphilis. *JAMA* LXVIII(14):1024–28.
- Wood JW, Milner GR, Harpending HC, Weiss KM, Cohen MC, Eisenberg LE et al. 1992. The Osteological Paradox: Problems of Inferring Prehistoric Health from Skeletal Samples [and Comments and Reply]. *Curr Anthropol* 33(4):343–70.
- World Health Organization. 2007. Exposure to mercury: A major public health concern. [pdf]
- World Health Organization. Available at: <http://www.who.int/phe/news/Mercury-flyer.pdf>. [Accessed March 14 2017].



- Yang KL. 1940. Clavicle sign of late congenital syphilis: Review of literature and report of six cases. *Arch Derm Syphilol* 41(6):1060–65.
- Zambrano M, Nikitakis NG, Sanchez-Quevedo MC, Sauk JJ, Sedano H, Rivera H. 2003. Oral and dental manifestations of vitamin D-dependent rickets type I: Report of a pediatric case. *Oral Surg Oral Med Oral Pathol Oral Radiol Endod* 95(6):705–9.
- Zuckerman MK. 2016. More harm than healing? Investigating the iatrogenic effects of mercury treatment of acquired syphilis in post-Medieval London. *Open Archaeol* 2(1):42–55.