



# Evidence of interpersonal violence or a special funeral rite in the Neolithic multiple burial from Koszyce in southern Poland – a forensic analysis

Tomasz Konopka<sup>1</sup>, Anita Szczepanek<sup>2</sup>, Marcin M. Przybyła<sup>3</sup>, Piotr Włodarczak<sup>4</sup>

<sup>1</sup>Department of Forensic Medicine, Jagiellonian University Collegium Medicum, Cracow, Poland

<sup>2</sup>Department of Anatomy, Jagiellonian University Collegium Medicum, Cracow, Poland

<sup>3</sup>PRYNCYPAT Marcin Przybyła, Poland

<sup>4</sup>Institute of Archaeology and Ethnology, Polish Academy of Sciences, Cracow, Poland

**ABSTRACT:** This study uses anthropological and forensic medical analyses to determine the cause of fractures found in the remains of 15 individuals buried at a site associated with the Globular Amphora Culture (2875–2670 BC). The intent was to determine the mechanism underlying the injuries and to indicate the types of tools that might have inflicted the blows. The fractures were diversified in their forms, but the majority of the injuries appear to have been inflicted by a flint axe, which is frequently found in graves of the Globular Amphora Culture. Apart from the forearm being severed in one of the victims, all the remaining skeletons showed from 1 to 4 injuries involving solely the skulls. The grave might contain victims attacked by invaders who executed the captives, or else the feature is ritual in character and it reflects the beliefs of the Neolithic community.

**KEY WORDS:** Neolithic, Globular Amphora Culture, multiple grave, violence, skull fractures

## Introduction

Recent decades have brought many new reports of skirmishes and warfare, documented for various European Neolithic societies (e.g. Walker 2001; Wahl and Trautmann 2012). This is confirmed

by signs of injuries left in the bones of skeletons. The location and nature of the marks clearly indicates intentional acts of violence (e.g. Meyer et al. 2009; Lorkiewicz 2012; Schulting and Fibiger 2012). Traumatic injuries that are found in the skeletal remains provide the most direct evidence of violence. The distinc-

tive features indicating violence include the nature of the injuries, such as their location on the body, signs of healing, and types of damage that could be associated with the implicated weapons (Schulting and Fibiger 2012). Sometimes items of weaponry, such as arrowheads, are embedded in human bones (Meyer et al. 2009). Traumatic skull lesions often occur as fractures induced by different types of edged weapons (Kaufman et al. 1997). The most important task in providing proper identification of an injury is to distinguish violent trauma from postmortem modifications.

Previous excavations have shown that societies of the Globular Amphora Culture buried most of their dead in multiple or collective graves (categories of graves after Duday 2009). Some of these graves contain burials showing traces of ritual practices, such as dismembered or partially burnt bodies (Nosek 1967). However, such remains have not yet been subjected to medical forensic analysis.

Evidence of lethal violence by purposefully inflicted injuries can be found in other regions of Neolithic Europe, for example in graves of the late Neolithic Corded Ware Culture discovered in Eulau, Germany (Meyer et al. 2009). From earlier times (the Linear Pottery culture), a collective grave with 34 individuals, some of whom had injuries characteristic of those sustained in a fight, was discovered in Talheim in Germany (Wahl and Trautman 2012). Another example of victims of violence associated with the Linear Pottery Culture is found in collective graves from Schletz, Austria (Teschler-Nicola et al. 1999). In both of the above-mentioned cases, the funeral rites typical of the culture were not maintained; the victims of Talheim were haphazardly heaped in a simple pit,

while in Schletz, the corpses were covered with soil in a ditch surrounding the settlement. In addition, in both cases, the bodies were buried some time after death, which is indicated by marks of animal foraging.

The newly explored multiple grave of the Globular Amphora Culture from site 3 in Koszyce (southern Poland) is a spectacular discovery, providing very valuable information about the problems discussed here. The key to interpreting this find is to determine the nature of the injuries found in the skull bones of nearly all individuals. Injuries were found in the skulls of males, females and children; therefore, no selecting process was employed that would take into account age or sex. The most important question to answer is whether the feature is indicative of rituals involving human and animal sacrifice or whether it is a multiple burial of people who died in some tragic circumstances. To resolve this dilemma, a forensic medical analysis of the injuries identified on the skeletons from Koszyce was performed.

## Material and methods

In 2011, during the archaeological rescue excavations conducted on site 3 in Koszyce, an assembly of two features, dated to the turn of the Late and Final Neolithic and related to the Globular Amphora Culture, was discovered (Fig. 1). The grave (feature No. 523) contained the remains of 15 individuals of variable age and sex. Rich burial goods consisted of: six pottery vessels, seven flint axes, 47 other flint artifacts (tools and flakes), three bone tools, 13 boar tusks, eight amber ornaments, two bone pendants and six animal bones without signs of heating. Based on eight radio-

carbon dating procedures, the absolute chronology of the grave was established at the interval between 2875–2670 BC. Close to the human grave, an animal burial was discovered, which contained skeletal remains of seven pigs (Przybyła et al. 2013).

The ages of the deceased were estimated using classic investigative methods based on skeletal development (Scheuer and Black 2000), and the sex estimation of adult individuals was based on anatomical dimorphic features (Ubelaker 1989, White and Folk-



Fig. 1. Multiple burial No. 523 from site No. 3 at Koszyce. A – Location of Koszyce on the map of Poland, B – Mutual location of a human grave and an animal burial place, C – Photography of a human grave.

Table 1. Anthropological classification of particular skeletons and description of injuries.

Skeleton No.	Age	Sex	Injuries (type of fracture in parentheses)
1	<i>adultus</i>	female	A round opening, 4 cm in diameter, in the anterior part of the right parietal bone (IV); an oval opening measuring 3×3.5 cm in the superior left part of the occipital squama (IV); a fragment of an opening in the margin of a larger bone defect in the posterior part of the right parietal bone, with a 3.5 cm long arch (IV).
2	<i>infans I</i> (1.5–2 years)	undetermined	Numerous fractures forming a long rectangle, 4–5 cm in width and with one side ending with an arch (V).
3	<i>adultus-maturus</i>	female	Above the left superciliary arch, a rounded opening 3.5×2 cm in size (VI); in the anterior part of the right parietal bone, a rounded opening measuring 5×3 cm (VI); in the central part of the right parietal bone, a rounded opening measuring 2.5×2 cm (VI).
4	<i>iuvenis</i> (16–17 years)	probably female	In the center of the right parietal bone, a rectangular opening measuring 2.5×0.5 cm (I); in the anterior part of the right parietal bone, an irregular opening measuring 2×1 cm (II); at the junction of the right parietal bone and the occipital squama, an irregular opening measuring approximately 1×1 cm (II).
5	<i>adultus</i>	male	In the central part of the left parietal bone, a drop-shaped opening measuring 3.5×2 cm (IV); in the center of the right parietal bone, oval cracking of the external table of the skull only, measuring 3×2 cm (IV); in the frontal squama, a small, irregular opening (II); in the central part of the occipital squama, an irregular opening measuring approximately 2×1 cm (II); a defect of the proximal epiphysis of the right humeral bone with visible parallel flaking of small bone fragments; defects of the proximal epiphyses of the right radial and ulnar bones at the same level.
6	<i>infans II</i> (13–14 years)	undetermined	In the central part of the right parietal bone, in the margin of a larger bone defect, a fragment of a semicircular opening, 17–18mm in width; in the occipital squama (IV), in the margin of a larger bone defect, marks of two separate arch-shaped openings, 3 and 4 cm in length, with margins expanding towards the interior of the cranium (IV) (IV); in the antero-lateral part of the left parietal bone, an irregular small defect (II).
7	<i>infans I</i> (2–2.5 years)	undetermined	No injuries can be unambiguously determined.
8	<i>adultus</i>	female	In the left part of the occipital squama, in the margin of a larger bone defect, a fragment of a round opening approximately 3 cm in diameter (IV).

ens 2005). The anthropological analysis demonstrated that grave No. 523 contained the remains of 15 individuals (Table 1). All age categories (*infans* – *maturus* – *senilis*) were represented. The distribution of age and sex, which includes older children, adolescents and young adults, resembles the living distribution rather than typical mortality profiles (Paine 2000).

Taking into account the age, sex and number of individuals in the burial, it could be hypothesized that these individuals belonged to the same community. The remains did not show the occurrence of any long-term illnesses, and the process of growth of young individuals did not differ from the same process observed in contemporary rural populations, which indirectly points to relative-

Table 1. cont.

Skeleton No.	Age	Sex	Injuries (type of fracture in parentheses)
9	<i>infans II/iuvenis</i> (15–16 years)	undetermined	A regular rectangular opening measuring 3.5×1 cm in the left lambdoid suture (I).
10	<i>iuvenis</i>	male	In the right and left part of the occipital squama, two round openings 3.5 cm (IV) and 4.5 cm (IV) in diameter; in the posterior-lateral part of the right parietal bone, in the margin of a larger bone defect, a fragment of an opening approximately 3 cm in diameter (IV).
11	<i>maturus</i>	male	In the central part of the right parietal bone, a drop-shaped opening measuring 2.5×3.5 cm (IV); in the left part of the frontal squama, an irregular opening (II).
12	<i>adultus-maturus</i>	female	In the frontal squama, on the right side, in the margin of a larger bone defect, a fragment of an irregular opening (II); in the occipital squama, on the left side, in the margin of a larger bone defect, a fragment of a round opening approximately 4 cm in diameter (IV); in the right side of the cranial vault, the bones are partially charred.
13	<i>infans I</i> (5–6 years)	undetermined	In the left parietal bone, close to the coronal suture, a large fragment of a round opening approximately 4cm in diameter (IV); in the posterior part of the left parietal bone, an irregular opening measuring 1×1.5 cm (III).
14	<i>maturus-senilis</i>	female	In the posterior-lateral part of the left parietal bone, an irregular opening measuring 2×1 cm (III); in the central part of the occipital squama, an irregular opening measuring 5×4 cm (II); in the central part of the frontal squama, an irregular opening measuring 1×0.5 cm (II). One of the skull fragments forming the cranial vault is partially charred in spite of the fact that the remaining, perfectly matched fragments do not manifest any signs of being subjected to fire.
15	<i>maturus</i>	male	In the center of the left parietal bone, in the margin of a larger bone defect, a fragment of an oval opening, 1.5 cm in width (IV); in the center of the right parietal bone, an irregular opening measuring 3×2.5 cm (II); in the area of the left lambdoid suture, a fragment of an irregular opening in the margin of a larger bone defect (II); a fracture of the left mandibular ramus, the margin of the fracture is not perpendicular but has an oblique course, expanding internally.

ly good living conditions (Szczepek 2013).

Postcranial skeletons of all the individuals were well preserved, but their skulls were considerably fractured. The aim of the forensic medical analysis of the reconstructed crania was to determine the mechanism by which these injuries had occurred and the types of tools used to inflict those injuries. The first stage

of the analysis is to determine the time (ante-, peri- or postmortem) of traumatic incidents visible in the skulls. If there is any noticeable evidence of healing, the trauma was unquestionably antemortem, but it may take at least a week, and often more for such changes to be visible on the surface of a bone (Kaufman et al. 1997). Unfortunately, when only bone remains are examined, no method

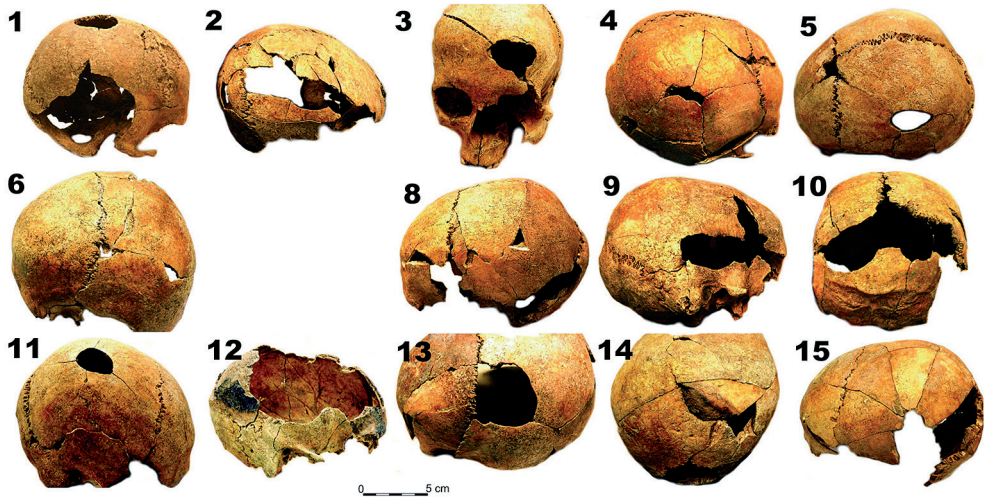


Fig. 2. Reconstructed skulls from grave 523 in Koszyce.

is available that would allow for unambiguous determination of whether a perimortem fracture was inflicted when the victim was alive or soon after death. Nevertheless, there are known properties that allow for determining whether the injuries occurred within this perimortem period, during which the bones demonstrate a degree of elasticity and generally retain some soft tissue, or whether they occurred in the postmortem period, after decomposition of the soft tissue (Maples 1986, Wieberg and Wescott 2008, Christensen et al. 2014).

The skulls of the individuals buried in grave No. 523 demonstrated a total of at least 36 blows (Fig. 2), which allowed for the investigation of various cranial fractures, the majority of which were inflicted with a single type of a tool. However, incidental tools could have been employed; in that case, presumably flint axes were used. As was mentioned above, seven such artifacts were found in the multiple grave. Apart from the analysis of the diversity of cranial fractures, we also attempted to reconstruct the se-

quence of the events that might have occurred before inhumation, and the possible motives of the perpetrators.

## Results

The investigation of the Koszyce skeletons demonstrated the presence of breakage originating from the postmortem period, predominantly involving the ribs and other fragile bones, but to a lesser degree also affecting larger bones, including the skulls. The above breakage can be primarily attributed to long-term pressure exerted by overlying earth on bones weakened by decomposition processes. In addition to numerous breakages originating from the postmortem period, the forensic-medical analysis of the skeletons also demonstrated the presence of fractures that must have occurred in the perimortem period, almost all of which involved the cranium. In the well-preserved postcranial skeletal remains, the authors succeeded in finding only one perimortem injury. This was a defect in the distal epiphysis of the right humeral

bone of skeleton No. 5, with the margins showing visible marks of parallel flaking of small bone fragments, as well as defects of the proximal epiphyses of the right radial and ulnar bones at the same level (Fig. 3).

Apart from the single fracture of the mandibular ramus (skeleton No. 15), all the remaining signs of injuries were noted within the cranial vaults. The facial parts of the skulls, and in the majority of cases also the bases, were so damaged that no reconstruction was possible. The authors also failed to reconstruct skull No. 7 of an individual at the *infans I* age (2–2.5 years of life). In view of the character of the grave, it should be assumed



Fig. 3. Signs of fractures in the bones of the right forearm and arm, skeleton No. 5. A – defects of the proximal epiphyses of the right radial and ulnar bones, B – defect of the distal epiphysis of the humeral bone.

that the skull was also damaged by intentional injury. Investigations of the remaining 14 skulls demonstrated from 1 to 4 marks each on the bones of the cranial vault. The marks had the form of holes that varied in shape, up to 4.5 cm in size, with radial cracks extending from the margins of the openings (Table 1), and appeared to have been inflicted by a tool with a small striking surface.

The properties that indicated the marks had been formed in the perimortem period included internal beveling, i.e. the opening being expanded towards the interior of the cranium, and flaking, i.e. signs of small bone fragments flaking off the fracture margin. In one case (skull No. 3), hinge fractures were found, wherein small pieces of bone remained attached to the fracture margin (White and Folkens, 2005). In several instances, the investigators observed concomitant circular cracks surrounding the defect at a distance of several centimeters. All these properties indicate that at the moment of impact, the bones demonstrated some elasticity typical for a fresh bone and not encountered in dry bone (Christensen et al. 2014).

Investigations allowed for determining several types of fractures, the infliction of which was not associated with taphonomic factors.

Type I, a rectangular opening demonstrating internal beveling of the skull, i.e. the surface of the break is situated at an angle to the surface of the bone and the opening in the inner table of the skull is larger than the hole in the outer table (Fig. 4).

Type II, an irregular opening, generally small in size, demonstrating internal beveling, with several (3–5) long cracks radiating from the margins of the defect (Fig. 5).



Fig. 4. Type I fractures, skulls No. 4, 9.



Fig. 5. Type II fractures, skulls No. 15, 14, 5.



Type III, an irregular opening as in type II, but with a concomitant circular crack surrounding the defect at a distance of several centimeters. Such a crack is an effect of deflection of more distant parts of the cranial vault (Fig. 6).

Type IV, a round, oval or drop-like, fairly regular opening, 3–4.5 cm in length, 2–4 cm in width, with margins being expanded towards the interior of the cranium, and in the majority of cases with signs of small bone fragments flaking off the fracture margin and concomitant radial cracks. It was the most common fracture type in the investigated skulls (Fig. 7).




Fig. 6. Type III fracture, skull No. 14, arrows indicate the bone fracture lines.

Type V, numerous fractures forming a long rectangle, 4–5 cm in width and with one side ending with an arch. Such a fracture was seen only in skull No. 2,




Fig. 7. Type IV fractures; seen from above and on the left, skulls No. 1, 11, 1, 6, 5, 13.

which consisted of very thin bones and belonged to a child.

Type VI, an opening with margins shaped as fairly regular arches with a radius of approximately 1cm; close to the margin, were concomitant arch-shaped cracks of the outer table of the skull. The opening demonstrated internal beveling. Such fractures were observed only in skull No. 3.

In skull No. 5, in addition to a type IV hole in the center of the left parietal bone, an oval crack of the outer table was seen, similar in size and situated symmetrically in the center of the other parietal bone; centrally in the crack, there was a superficial scratch. The scratch ex-

tended along the long axis of the oval defect and measured 20×2 mm. The inner table demonstrated several short, radiating cracks, with slight internal beveling.

The distribution of classification of blow marks in particular skulls is presented in Fig. 8.

Two skulls displayed signs of charring. Skull No. 12 showed an extensive defect of the cranial vault, the margins of which were charred spanning the major part of its circumference. In turn, in the case of skull No. 14, when all the fragments (both connected to the skeleton and lying loosely in the grave) were refitted and glued, only a single fragment turned out to be partially charred. Interestingly,

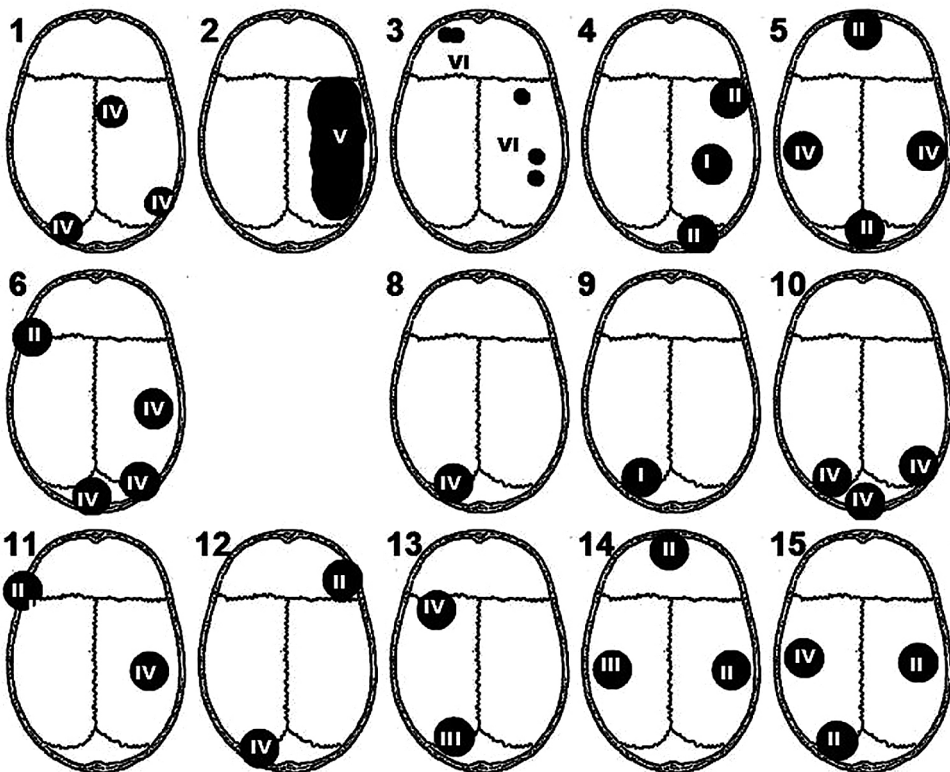


Fig. 8. Distribution of blow marks in particular skulls with blow type determination.

fragments situated in its vicinity, including those adjacent to the charred site, did not show any traces of fire.

## Discussion

The grave from Koszyce, showing such an exceptional treatment of the deceased, has become the first Neolithic burial in the territory of Poland subjected to such an analysis. The burial took place soon after the death of the individuals. This is indicated by the anatomical layout of the skeletons, the preserved bones of the hands and feet, and the complete sequence of all the vertebrae as well as the mandibles lying close to the crania. This feature clearly differs from the examples of multiple and collective graves described in the introduction. An almost complete absence of injuries involving body parts other than the skulls proves that the individuals buried in the grave decidedly did not perish during hand-to-hand fighting. The injuries seen in the skulls were inflicted in a purposeful manner; they do not represent accidental damages sustained during a fight. With the exception of skull No. 1, where one injury is situated in the apical part, in all other skulls the blows were delivered to the circumference of the head. Moreover, none of the skulls displayed superimposition of blow marks, even if they were situated on the same side of the head. Injuries sustained in such an arrangement are possible only when the victim is immobilized and the position of the body is changed after each blow. It cannot be ruled out that the strikes were inflicted postmortem.

The analysis of the character of the fractures suggests that – with the exception of skulls No. 2, 3 and 7 – damages seen in all the remaining skulls might

have been inflicted by the same tool or by tools of the same type. The most likely tool to be used by the peoples of the Globular Amphora Culture seems to be a flint axe.

The mechanics of cranial fractures resulting from a blow inflicted by a blunted tool has been studied by forensic medicine specialists since mid-19th century; experimental studies were carried out by such authors as Messerer (1884), Paltauf (1888) and Casper (1889). It is these oldest reports that provided conclusions indicating, for example, that a blow inflicted by a large-surface tool results in a linear fracture of the skull surface, while a small-surface tool causes cranial indentations. Experimental studies employing modern measurement methods were continued in the forties and fifties of the 20th century. The most extensive investigations were carried out by Gurdjian (Gurdjian et al. 1950, Gurdjian 1961). Similar experiments, but on a smaller scale, were conducted in Poland, in the Department of Forensic Medicine in Cracow (Smolaga et al. 1955). Experiments carried out on corpses demonstrated that tools with small striking surfaces wielded at high energy caused indentation and perforation of the cranium in a shape corresponding to the surface of the tool. If the blow was inflicted with a corner of the experimental tool (e.g. a hammer head), only radial cracks occurred, extending from the site of contact between the tool and the bone, while at the very site of the contact, a non-characteristic indentation was formed. In some cases, especially when the striking velocity was low, concentric cracks developed that surrounded the impact site at some distance. In all cases, however, such openings showed internal beveling (Gurdjian et al. 1950, Smolaga et al. 1955).

The shape of the cross-section of the Globular Amphora Culture axe or chisel corresponds to the shape of rectangular openings found in the skulls of adolescents No. 4 and 9 (type I). (Fig. 9). Most likely, the close reproduction of the tool shape in these cases resulted from low hardness and possibly elasticity of the cranial bones. Differences in the size of the openings ( $3.5 \times 1$  cm in skull No. 9 and  $2.5 \times 1$  cm in skull No. 4) may be a result of two axes having been employed. The type II fracture in the form of an irregular defect with radiating cracks does not allow for unambiguous determination of the employed tool. Most likely, however, this is the appearance of markings left after a blow inflicted by a corner of a flint axe head. This is more likely in view of the fact that this very type of a tool re-

sulted in the most commonly seen fracture – a round or oval opening (type IV).

It might seem that round holes were formed following blows inflicted by tools with round-shaped cross-section; nevertheless, skull No. 5 showed marks that helped to determine the mechanism by which such an opening occurred. In skull No. 5, similarly as in several other skulls, blow marks were arranged symmetrically on the lateral surfaces of the head, which suggests that both strikes were delivered with the same tool, one after another. As a consequence of the blow, an oval hole was formed in the left parietal bone, while on the right side, there was only an oval crack of the outer table having the same size. However, in the central part of the oval lesion, there is a linear scratch of the bone surface.

As described in the experimental papers mentioned above, the formation of an oval defect, in the case of a blow inflicted by the blade of a stone axe, is a result of the bone deflecting within a radius of several centimeters from the site of impact of the tool (as in type III fracture) and the formation of a crack widely encircling the site (Gurdjian et al. 1950). In this case, the entire fragment was pushed into the cranium, resulting in the formation of a round or oval defect. Bone fragments found inside skull No. 1 were successfully used to reconstruct fragments that fitted the round openings. The scratch markings in the centre of the oval in the right parietal bone of skull No. 5 indicated that the employed tool had a 2 cm-long edge (Fig. 10).

Openings similar to the type IV fracture described by Spencer (2012) in the skulls originating from the Schild site and belonging to pre-Columbian Amerindians of Illinois were interpreted as marks left by blows inflicted by a celt, which is




Fig. 9. Flint tools of the Globular Amphora Culture: A, B – axe blade, C – chisel blade.




Fig. 10. A mark in skull No. 5 – an oval crack of the outer table; in its centre, a linear scratch at the site of the stone tool impacting the bone.

the ground stone bit of the hatchet commonly referred to as a tomahawk.

Blow marks in the three remaining skulls were inflicted by other tools. In skull No. 2, belonging to a child, the fractures involved a relatively sharply delineated area 10 cm in length and 4–5 cm in width. This could be a mark left after a blow inflicted by a bludgeon-type tool; it is likely that a tool of the same kind caused fractures in the skull of the second child at the same age (No. 7), which, in the case of thin bones, resulted in complete crushing of the cranium.

On the other hand, a completely different tool and most likely a different mechanism of action were employed in the individual numbered 3. The tool employed had a round cross-section and a diameter of 1.5–2 cm. The opening in the frontal squama appeared to result from two perpendicular blows inflict-

ed closely together with a tool of circular cross-section, with bone fragments crumbling in between. Delivering two blows spaced so closely together with a similar force suggests that they were struck in a more precise manner than in the case of the other skulls. Possibly, the perpetrator hit an intermediate tool placed against the head of the victim, as when a punch or a chisel is hit with a hammer. Archaeological literature on the Neolithic era mentions tools of this type fashioned from a section of deer antler. A case was described of finding a skull with a tool defined as a perforator lodged inside such a hole (Ahlström and Monar 2012).

All of the above-described bone injuries were sustained perimortem. This is confirmed by both the character of the margins of the damaged bones (see White and Folkens 2005, Fibiger 2012,

Christensen et al. 2014), and the absence of signs of bone healing manifested as bone tissue regeneration. The term “perimortem” accounts for injuries that might have constituted the cause of death of the buried individuals, as well as injuries inflicted soon after death, when the bone still maintained the properties of living tissue. In consideration of the circumstances and motivations of the homicides, most likely of a ritual character, an analysis of such prehistoric cases escapes the experience of forensic medicine, which is mainly based on contemporary cases. However, interesting information in this respect was provided by skull No. 14. Finding within the skull a single charred fragment side by side with others, showing no thermal changes, indicates that only this fragment was exposed to fire. This in turn suggests that in the period between inflicting the blows and burying the body, the fragment must have been completely detached from the remaining parts of the head and exposed to fire. Such a large fragment could not possibly have fallen out in consequence of a blow to the head. This implies that bone fragments were intentionally removed following the administration of a blow to the head and, most likely, the dissection of the epicranium. In such a situation, blows to the head from several directions might have aimed at “splitting” the skulls, possibly to gain access to their interior. Should this be the case, the justification of a collective murder was most likely provided by religious considerations that sanctioned a blood sacrifice. The fact that in almost all the skeletons, the damage involved only the skulls also points to ritual activities. Such a scenario is typical

of ritual injury is encountered in various prehistoric and historic periods. A focus of violence mainly to the head of the attacked individual likely springs from both strategic and psychological reasons (Fibiger 2012). It should be emphasized that in Koszyce, injuries were found in the skulls of males, females and children; therefore, no selecting process was employed that would take into account age or sex.

It is also not possible to completely rule out a scenario in which the individuals buried in the Koszyce grave were killed by strangers, also for ritual purposes. The assailants might have belonged to the same material culture as their victims (the Globular Amphora Culture), or else represented a different model of culture, associated with the late Neolithic period (the Corded Ware Culture). Nevertheless, the burial of the dead must have been performed by members of their local group.

An alternate theory explaining the collective homicide is the performance of a specific burial rite, during which the corpses were subjected to such procedures. An element of these rites may be the opening of the skulls. To date, no such practice has been described in case of the Globular Amphora Culture; nevertheless, the majority of the analyzed funeral objects originating from the culture were studied in mid-20th century and no forensic-medical examinations were performed. Obviously, in such a situation, it should be assumed that all the individuals buried in the Koszyce grave died at the same time by causes leaving no markings in the bones, e.g. in consequence of an epidemics, flood, freezing weather or another natural disaster.

## Conclusions

Summing up the considerations of the genesis of the multiple grave from Koszyce, one may propose two hypotheses. The first possible scenario is that the individuals buried in grave No. 523 were killed by their kinsmen or by strangers, who thus fulfilled a ritual act that reflected the beliefs of their community. Alternatively, one might consider a possibility that the majority of the individuals buried in the grave were killed in a rite associated with the burial of a single person.

The latter hypothesis assumes that delivering blows to the head, most likely associated with opening the skulls, occurred after death, which might have resulted from natural causes. Possibly, in this way, a specific burial-associated rite was performed.

Despite their variable character, all the injuries seen in 12 of the 15 investigated skulls might have been inflicted by a single tool type – a flint axe or chisel. Depending on the force of a blow and most likely also on the hardness of the bone, the tool might have caused a rectangular indentation, an irregular opening or a round or oval hole. The three remaining skulls demonstrated injuries that might have resulted from a blow delivered by a bludgeon and a chisel-type tool of small diameter. The location of injuries in the skulls excludes scenarios in which they were sustained in combat.

## Acknowledgements

The authors thank Mark Toussaint, University of Nevada, Las Vegas for language correction of the text.

## Authors' contributions

Each author has prepared his/her own part of the manuscript according to the subject of interest and the final version is the result of a team work. TK: forensic medical analysis of skull fractures (idea of manuscript, introduction, methods, results, discussion, conclusion); ASz: anthropological analysis of buried individuals, interpretation of the funeral rite (introduction, material, methods, discussion, conclusion); MP: analysis of archaeological material, interpretation of the funeral rite (introduction, material, discussion, conclusion)

PW: analysis of archaeological material, interpretation of the funeral rite (introduction, material, discussion, conclusion). All authors have critically read and approved the final version of the manuscript for submission.

## Conflict of interest

The authors declare that there are no conflicts of interest.

## Corresponding author

Tomasz Konopka, Department of Forensic Medicine, Jagiellonian University Collegium Medicum, Grzegórzecka 16, 31-531 Kraków, Poland  
e-mail address: konopkat@wp.pl

## References

- Ahlström T, Monar P. 2012. The placement of the feathers: violence among sub-boreal foragers from Gotland, central Baltic Sea. In: R Schulting and L Fibiger, editors. *Sticks, stones and broken bones: Neolithic violence in a European perspective*. Oxford: Oxford University Press. 17–34.

- Casper J. 1889. *Handbuch der gerichtlichen Medizin*. Berlin.
- Christensen AN, Passalacqua NV, Bartelink EJ. 2014. *Forensic Anthropology. Current Methods and Practice*. Elsevier Inc.
- Duday H. 2009. *The Archaeology of the Dead. Lectures in Archaeoethanatology*. Oxford: Oxbow books.
- Fibiger L. 2012. Investigating cranial trauma in the German Wartberg Culture. In: R Schulting and L Fibiger, editors. *Sticks, stones and broken bones. Neolithic violence in the European perspective*. Oxford: Oxford University Press. 175–89.
- Gurdjian ES. 1961. Experiences in head injury and skeletal research. In: *Impact acceleration stress. A Symposium held at Brooks Air Force Base, November 1961*, Washington. 145–57.
- Gurdjian ES, Webster JE, Lissner HR. 1950. The mechanism of skull fracture. *J Neurosurg* 7(2):106–14.
- Kaufman MH, Whitaker D, McTavish J. 1997. Differential Diagnosis of Holes in the Calvarium: Application of Modern Clinical Data to Palaeopathology. *J Archaeol Sci* 24:193–218.
- Lorkiewicz W. 2012. Skeletal trauma and violence among the early farmers of the North European Plain: evidence from Neolithic settlements of the Lengyel Culture in Kuyavia, north-central Poland. In: R Schulting and L Fibiger, editors. *Sticks, Stones and broken bones: Neolithic violence in a European perspective*. Oxford: Oxford University Press. 51–76.
- Maples WR. 1986. Trauma analysis by the forensic anthropologist. In: KJ Reichs, editor. *Forensic Osteology: Advances in the Identification of Human Remains*, Springfield: Charles C. Thomas. 218–28
- Messerer O. 1884. *Experimentelle Untersuchungen über Schadelbrüche*. München.
- Meyer C, Brandt GD, Haak W, Ganslmeier RA, Meller H. 2009. The Eulau eulogy: Bioarcheological interpretation of lethal violence in Corded Ware multiple burials from Saxony-Anhalt, Germany. *J Anthropol Archaeol* 28:412–23.
- Nosek S. 1967. *Kultura amfor kulistych w Polsce*. Prace Komisji Archeologicznej t. 8. Polska Akademia Nauk.
- Paltauf A. 1888. Über die Gestalt der Schädelverletzungen. *Vierteljahrsschrift für die Gerichliche Medizin* 48:322–47.
- Paine RR. 2000. If a population crashes in prehistory, and there is no paleodemographer there to hear it, does it make a sound? *Am J Phys Anthropol* 112:181–90.
- Przybyła MM, Włodarczak P, Podsiadło M, Tunia K. 2013. *Obiekty kultury amfor kulistych (Features of the Globular Amphora Culture in Koszyce)*. In: MM Przybyła, A Szczepanek and P Włodarczak, editors. *Koszyce, stanowisko 3. Przemoc i rytuał u schyłku neolitu*. *Ocalone Dziedzictwo Archeologiczne t. 4*. 11–64.
- Scheuer L, Black S. 2000. *Developmental juvenile osteology*. Elsevier Ltd.
- Schulting R, Fibiger L. 2012. Skeletal evidence for interpersonal violence in Neolithic Europe: an introduction. In: R Schulting and L Fibiger, editors. *Sticks, stones and broken bones: Neolithic violence in a European perspective*. Oxford: Oxford University Press. 1–16.
- Smolaga J, Tomaszewski M, Koźmińska A. 1955. *Studia krytyczne i doświadczalne nad rozpoznawaniem użytego narzędzia z wyglądu obrażenia*. 1. Rozpoznanie narzędzia tępego na podstawie złamań czaszki (Critical and experimental studies on determination of the employed tool based on the appearance of the injury. 1. Determination of a blunt instrument based on skull fractures). *Arch Med Psych Sad Krym* 6:132–48.
- Spencer SD. 2012. Detecting Violence in the Archaeological Record: Clarifying the timing of trauma and manner of death in cases of cranial blunt force trauma among pre-Columbian Amerindians of West-Central Illinois. *Int J Paleopathol* 2(2–3):112–22
- Szczepanek A. 2013. *Analiza antropologiczna szkieletów (Anthropological analysis of skeletons)*. In: MM Przybyła, A Szczepanek and P Włodarczak, editors. *Ko-*



- szyce, stanowisko 3. Przemoc i rytuał u schyłku neolitu. *Ocalone Dziedzictwo Archeologiczne* t. 4. 65–91.
- Teschler-Nicola M, Gerold F, Bujatti-Narbeshuber M, Prohaska T, Latkoczy CH, Stinger G, Watkins M. 1999. Evidence of Genocide 7000BP – Neolithic Paradigm and Geo- climatic reality. *Coll Antropol* 23(2):437–50.
- Ubelaker DH. 1989. *Human skeletal remains. Excavation, analysis, interpretation.* Washington: Taraxacum.
- Wahl J, Trautman I. 2012. The Neolithic massacre at Talheim: a pivotal find in conflict archaeology. In R Schulting, L Fibiger, editors. *Sticks, stones and broken bones: Neolithic violence in a European perspective*, Oxford: Oxford University Press. 77–100.
- Walker PL. 2001. A bioarchaeological perspective on the history of violence. *A Rev Anthropol* 30: 573–96.
- White T, Folkens P. 2005. *The Human Bone Manual*, Burlington-San Diego-London: Elsevier.
- Wieberg DAM, Wescott DJ. 2008. Estimating the Timing of Long Bone Fractures: Correlation Between the Postmortem Interval, Bone Moisture Content, and Blunt Force Trauma Fracture Characteristics. *J Forensic Sci* 53(5):1028–34.
- Wiślański T. 1969. *Podstawy gospodarcze plemion neolitycznych w Polsce północno-zachodniej.* Wrocław–Warszawa–Kraków: Zakład Narodowy.